

Accuracy of Neck U/S in Comparison with Frozen Section in Suspicious solitary thyroid nodule.

Mohammed Shehata Zarad¹, Boshra Ali Ali Elhoseiny², Heba Anwar Shoman³, Amal H Ibrahim⁴, Tamer Mohamed Abd Elkader⁵, Marwa Mohy Eldin Abdelrahman Ahmed⁶, Sami Abdallah Mohamed⁷, Shimaa Mohamed Mohamed Ahmed⁸, Marwa Mostafa Fadel Sonbol⁹, Elsayed Mohamed Abd El-Hamid Hassan¹⁰

^{1,2}Department of surgery, Faculty Of Medicine For Girls, Al-Azhar University, Cairo, Egypt.

^{3,4} Department of Internal Medicine, Faculty Of Medicine For Girls, Al-Azhar University, Cairo, Egypt.

⁵ Department of Internal Medicine, Faculty Of Medicine, Al-Azhar University, Damietta, Egypt .

⁶Department of Internal Medicine, Faculty Of Medicine, Benha University, Egypt.

⁷Department of Pathology, Faculty Of Medicine, Al-Azhar University, Damietta, Egypt

^{8,9}Department of Radiodiagnosis, Faculty Of Medicine For Girls, Al-Azhar University, Cairo, Egypt.

¹⁰Department of Radiodiagnosis, Faculty Of Medicine, Al-Azhar University, Damietta, Egypt.

***Corresponding author:**

Mohammed Shehata Zarad

Email ID : zarad.moh@gmail.com

ABSTRACT

Background: The vast majority of the population, particularly women, frequently develop thyroid nodules. The therapeutic incidence is between 4% and 7%, but because of the extensive use of ultrasound (US), the incidence has climbed to approximately 67%. Today's surgeons use ultrasonography and frozen sections as their primary diagnostic tools when determining whether a lesion is cancerous.

Aim: The objective of the current survey was to compare the accuracy of ultrasound against frozen section in the detection of malignant, suspicious solitary thyroid nodules as well as evaluate the clinical pathology records. Materials and Methods: Using a normalised data collection format, the medical records of all individuals with suspicious solitary thyroid nodules attending This study was conducted at Al-Zahraa and Al-Azhar University Hospital, New Damietta, and was prospectively evaluated. Nodules were classified using the ACR TIRADS scoring system. The overall histology diagnosis was contrasted with the ultrasonography and frozen section findings. The following metrics were estimated: sensitivity, specificity, positive and negative predictive values, and likelihood proportions.

Results: There were 50 participants with solitary thyroid nodules; their ages ranged from 28 to 76, with a mean age of 53.4 ± 8.0 years. An anterior neck swelling (60%) was the most typical STN presenting symptom. Pain (20%), hoarseness (16%), and dysphagia (16%) were the other indications that were most prevalent. According to the results of the ultrasound examination, all patients proved to have suspicious thyroid nodules. Solitary thyroid nodules appear on the right side of the thyroid (68%) and the left side of the thyroid (30%), with one (2%) isthmic case. According to the TIRADS score, 18% of patients were mildly suspicious, 20% were moderately suspicious, and 58% of cases were highly suspicious. According to the FS classification, 70% of the suspicious solitary patients had malignant tumours, 10% had benign tumours, and indeterminate nodules were detected in 20% of the studied cases. The frozen section analysis showed a sensitivity of 67% compared to 89% in the ultrasound analysis. The specificity score showed that frozen sections recorded 96.6%, while ultrasound analysis recorded 93%.

Conclusion: To conclude, we can depend on US scanning for the diagnosis of malignant solitary thyroid nodules as a predictable tool in the absence of FS. However, in the presence of FS, it can support the diagnosis of malignant thyroid nodules.

Keywords: Ultrasound, frozen section, solitary, thyroid nodule, suspicious

How to Cite: Mohammed Shehata Zarad, Boshra Ali Ali Elhoseiny, Heba Anwar Shoman, Amal H Ibrahim, Tamer Mohamed Abd Elkader, Marwa Mohy Eldin Abdelrahman Ahmed, Sami Abdallah Mohamed, Shima Mohamed Mohamed Ahmed, Marwa Mostafa Fadel Sonbol, Elsayed Mohamed Abd El-Hamid Hassan, (2024) Accuracy of Neck U/S in Comparison with Frozen Section in Suspicious solitary thyroid nodule.. Journal of Carcinogenesis, Vol.23, No.1, 235-248.

1. INTRODUCTION

Up to 67% of elderly individuals and female patients have thyroid nodules. Thyroid nodules are a prevalent disease. The majority of nodules are benign, whereas 4% to 5% turn out to be cancerous in the end (1).

Around 50% of people over 40 have thyroid nodularity, which can range in incidence from 19% to 67% and worsen with age (2). The necessity of excluding thyroid cancer, which is discovered in 5–15% of patients according to sex, age, and susceptibility to other risk factors, is the clinical relevance of thyroid nodules. Smaller papillary thyroid tumours, the most sluggish kind of thyroid cancer, are primarily blamed for the almost fivefold rise in thyroid cancer rates during the past 50 years(3).

The history-taking, physical examination, assessment of thyroid stimulating hormone (TSH), and thyroid ultrasonography to describe the nodules all need to be part of the initial assessment for individuals with thyroid nodules. TSH monitoring alone could be sufficient to identify mild thyroid problems(4, 5, 6).

Thyroid ultrasound (US) is an important diagnostic technique for assessing thyroid lesions. It can identify lesions as tiny as 2 mm and offer details on size, structure, and parenchymal alterations(7). The distinction between benign and malignant lesions is frequently used to prevent the needless use of invasive procedures. Numerous characteristics have been connected to malignancy and identified as separate risk factors. These included enhanced vascularity, hypoechogenicity, a longer than wider form, uneven edges, and microcalcifications(8).

For the identification of thyroid nodules that are simply too tiny to be felt, the US has a higher sensitivity(9). These nodules could, therefore, be clinically insignificant. Incidental thyroid nodules were shown to have a malignancy rate of 24% in individuals who had already had an initial non-thyroid cancer diagnosis. This is significantly higher than the 5% predicted malignancy rate among individuals without additional primary tumours that are identified(10).

Over the past 40 years, the utilization of intraoperative frozen section (FS) has indeed been advocated as a method to customise the scope of the initialization step and acquire a conclusive histologic identification of a preoperatively ambiguous thyroid lesion diagnosed as follicular neoplasia. Furthermore, due to the differences in reported outcomes, its use sparks vigorous debate about its usefulness and cost-effectiveness(11).

It has lately been suggested that US and intraoperative FS can be useful in choosing the best operation to treat thyroid nodules that have been evaluated as suggestive for TC (12). Regional research on the sensitivity and specificity of ultrasonography and frozen section in assessing thyroid nodules for malignancy is still lacking, despite the large number of foreign studies that have been conducted in this area(13). The primary objective of the current study was to compare the effectiveness of U/S with FS in detecting suspicious thyroid nodules and to find the predictive error of U/S with the use of FS.

2. MATERIALS AND METHODS

Study design

The study was conducted prospectively on 50 adult thyroid gland patients to evaluate the clinical pathology records of solitary thyroid lesions for US and frozen section of the thyroid gland.

Study setting

This study was conducted at Al-Zahraa and Al-Azhar University Hospital, New Damietta.

Patients

All cases were examined at the general surgery and internal medicine outpatient clinics. Patients presented with swelling in the anterior aspect of the neck, pain, and hoarseness. Some patients had a high risk of hypertension, diabetes, or asthma. An ultrasound was requested on the neck as well as thyroid gland functions, and it appeared to be a suspicious solitary thyroid nodule.

Inclusion criteria

Patients of all ages and of both genders who presented with a suspicious solitary thyroid nodule in one lobe by U/S were included in the study.

Exclusion criteria

Kids, multi-nodular goitre (diagnostically or US-proven), past history of thyroid malignancy, and even past history of radiotherapy to the neck, pen open diagnosis to the neck, and any sign or symptoms of thyrotoxicosis or hypothyroidism, patients with previous thyroid surgery, and patients with histologically proven thyroid malignancy who had undergone preoperative FNA were excluded from the study.

Ethical considerations

The "Research Ethics Committee" at Al-Zahraa and Damietta University hospitals gave their permission to this investigation. The "Declaration of Helsinki" addressing studies with humans is intended to be followed by the article's protocols. Written consent for USFNAB had been obtained from each participant prior to biopsy, and the research project received approval from our institutional review board.

Data collection

Each participant in the research had (a) a thorough demographic, clinical, and history recording and symptoms; (b) an ultrasound examination by a radiologist; and (c) histopathological findings by frozen section.

All patients were subjected to:

1- Full history taking and much more attention was paid towards:-

Age and gender: Thyroid nodules in patients at the ages of high malignancy are concerning. Men are twice as likely as women to develop cancer if a thyroid nodule is detected.

Family history of thyroid cancer.

Size: Nodules greater than 4 cm in diameter could indicate a greater risk of malignancy.

Growth rate: Non-neoplastic goitres grow slowly and indolently over time. Weekly rapid increase is more strongly linked to cancer. Similarly to this, a sudden increase in the size of an already-existing nodule could be a sign of cancer. Yet, lymph nodes would encourage cancer if they were present.

Associated Symptoms: Screening for cancer is immediately required if there are substantial compressive and obstructing indicators, such as hoarseness and dysphagia.

Radiation Exposure: Individuals who have experienced neck radiation are at a higher risk of developing benign and malignant thyroid tumours, in addition to smoking or consuming alcohol.

2- Physical Examination

A physical exam includes a local thyroid assessment as well as a systemic check for signs of hypo- or hyperthyroidism, other cancerous lesions, or other causes. While other tumours outside of the thyroid do not move with swallowing, the thyroid gland and the nodules within it do. Other palpable nodules ought to be recorded for their existence, size, location, shape, consistency, and presence. A firm nodule is typically caused by autoimmune thyroid disease, whereas one with a stony hard nature is more likely to be malignant. Firm nodules that are fixed signal invasion and could be a sign of cancer. Pemberton's Indicator This symptom aids in determining the level of substernal extension for big thyroid lesions. When the patient is requested to extend his arms over his head, the mass enlarges or, if the mass has a significant substernal element, the airway is compressed by venous congestion. In order to check for detectable lymphadenopathy, the neck ought to be properly palpated. Multiple, massive, fixed lymph nodes that are firm to hard and firm to hard are signs of metastatic carcinoma, which can develop from the thyroid. Risk classification ought to be carried out following the history and physical examination, and the right tests ought to be chosen for a more thorough diagnosis.

3- Serology and Biochemical Tests

A serum TSH measurement is used as the first diagnostic test for all thyroid nodule individuals to establish whether they are hypothyroid, hyperthyroid, or euthyroid. When a patient has a thyroid nodule, most of them are euthyroid; if they are not, the underlying pathology is most likely benign and functional.

Given that a parathyroid adenoma might mimic a thyroid nodule, a baseline preoperative ionised calcium measurement is useful.

Surgical procedures

After an ultrasound examination, patients were transferred to the surgical department for surgery. On the basis of the outcomes of the examination and investigation of each subject, the choice to perform surgery was made. The majority of patients had their procedure planned out in advance. If a solitary thyroid nodule was detected using clinical and ultrasonography methods, the affected side underwent a hemi thyroidectomy, and the sample was submitted for a frozen section. While we opted to wait until the final histology analysis, a complete thyroidectomy was performed in the case of a malignant frozen section result. If benign or in the case of proved calcified thyroid nodules, patients underwent hemi-

thyroidectomy.

The location and kind of incision were chosen during the operation. Throughout the dissection, hemostasis, protection of the parathyroid, and other crucial structures, including the recurrent laryngeal nerves, were all addressed. The drainage was handled, and necessary measures were followed to treat postoperative hypocalcemia and anaemia. The final histology assessment was used to determine the course of treatment. The patients were handled by routine hormonal screening, with or without hormonal supplements, if the result was benign. The management of hypocalcemic symptoms involved calcium and vitamin D supplements. If the thyroid is malignant, patients are transferred to the oncology unit to complete management follow-up with both the endocrine and oncology units. Surgical follow-up for the detection of recurrent nodules in other lobes must be conducted. Regular follow-up was indicated for all subjects.

Image Analysis (Nodule analysis):

Through two-dimensional ultrasound scanning, an ultrasound test was done. Expert head and neck radiologists conducted ultrasound examinations and image acquisitions during each patient visit, utilising the 'Thyroid' settings and higher-frequency linear probes (6–15 MHz) on a 3D/ 4D Philips Affiniti 70 Ultrasound System (Philips Healthcare, Amsterdam, Netherlands) and (GE LOGIQ S8 ultrasound, Linear probe (6-15 MHz), Korea). Every assessment used a frequency of between 9 and 13 MHz, 1-2 focus zones that were centred on the area of concern, and spatially compounding (GE Logic S8 "cross-beam" imaging) technology. In several tests, colour Doppler was utilised as a problem-solving technique in conjunction with B-Mode (Brightness-Mode) gray-scale visuals. When used, the nodules under examination served as the Doppler coloured-flow area of interest, with the following restrictions: Acoustics output power: 1/4 of a hundred.

The ACR TIRADS scoring system was used to create the ultrasound reports. Other physicians' referrals of cancer with a biopsy-proven diagnosis and TIRADS 1 (normal thyroid gland) were disqualified. TIRADS 2 and 3 were recorded for benign-appearing nodules (if ≥ 2.5 cm and follow-up if ≥ 1.5 cm, respectively). During bedside ultrasonography conducted by the surgeon, indeterminate or suspected follicular lesions were recorded as TIRADS 4 (if ≥ 1.5 cm and follow-up if ≥ 1 cm) and malignant-appearing nodules were identified as TIRADS 5 (if ≥ 1 cm and follow-up if ≥ 0.5 cm).

The pertinent nodular structure, borders, echo-textures, echogenicity, compositions, calcifications, vascularity, comet tail artefact, echogenic foci, peripheral halo, and lymphadenopathy are all factors that define thyroid nodules: (a) There are two types of nodule shapes: broader than taller and taller than wider, (b) There are two types of nodule margins: smooth (regular) and lobulated (irregular), (c) The nodular' echo-texture characteristics were divided into homogenous and heterogeneous categories, (d) They can be anechoic, significantly hypoechoic (relative to strap musculature), hypoechoic (in comparison to the thyroid gland), iso-echoic, moderately hyperechoic, or strikingly hyperechoic in terms of echogenicity, (e) There were four types of nodular compositions identified: solid, cystic, mixed solid and cystic, and micro-cystic/spongiform, (f) The ring-down indicator is assessed for thyroid nodules with cystic transformation and documented colloid, (g) Mixed-element nodules were assessed based on their solid component, (h) Once calcifications do occur, their location is classified as central or peripheral, and they might take the form of eggshell, globular, or micro-calcifications, (i) Depending on whether or not a peripheral halo is observable, the nodules are categorized, (j) The nodules were divided into four categories based on their vascularity: central, peripheral, mixed, and none, (k) Any lymphadenopathy with a suspicious appearance in the context of a suspected cancer shall be regarded as a metastasis. Size greater than 10 mm, disappearance of the fatty hilum, rounding bulging form, uneven borders, heterogeneous echo textures, calcifications, cystic regions, or enhanced vascularity all through the lymphatic nodes are all signs of suspicious lymph nodes.

Frozen section biopsy

Representative lesions from tissue samples presented for FS were splatted, embedded in OCT compounds (Tissue-Tek, Miles Inc., Elkhart, IN), quickly frozen in a cryostat, cut into 6-mm slices, and labelled using a quick haematoxylin and eosin procedure(14). The same group of pathologists classified the findings as cancerous, benign, or non-diagnostic (i.e., a follicular tumour or lesion). By FS, we evaluated U/S performance.

Final histological diagnosis

After examining the permanent sections of the surgical samples obtained during the therapy process (thyroidectomy), a definitive histological diagnosis was made. After being fixed in 10% formaldehyde, handled with customary methods, and embedded in paraffin wax, tissue samples were cut into 3- to 5- μ m slices and stained with haematoxylin and eosin. The final histological diagnosis functioned as the gold standard to determine if thyroid cancer was present (malignant lesions) or not (benign lesions).

Statistical analysis

The statistical software for social science (SPSS) version 26 was used to conduct the analysis. While qualitative data was represented as numbers and frequencies, quantitative data was presented as mean \pm SD.

Results

General characteristics of the studied patients (n=50)

The majority of the patients with STN were female (92%), and 8% were male. The mean age of the study participants was 53.4 ± 8.0 with a wide range (min–max: 28–76) of years. 36% of patients aged between 21 and 30 years old were followed by those aged between 41 and 50 years old (20%). 60 % of patients presented with hypertension, 18% with asthma, and 10% with diabetes. The most common presentation of STN was swelling in the anterior aspect of the neck (60%). The other most common symptoms were pain (20%), hoarseness (16%), and dysphagia (16%). The duration of symptoms ranged from one to 90 months. According to the TIRADS score, 18% of patients were mildly suspicious, 20% were moderately suspicious, and 58% of cases were highly suspicious (Table 1).

Table (1): Features of the thyroids and the 50 participants' demographics who had suspicious thyroid nodules

Variable	N=50
Sex	
Female	46 (92%)
Male	4 (8%)
Age (years)	
Mean \pm SD	53.4 ± 8.0
Range (min-max)	(28-76)
<20 years	6 (12%)
21-30 years	18 (36%)
31-40 years	9 (18%)
41-50 years	10 (20%)
51-60 years	6 (12%)
>60	1 (2%)
Patients history	
Hypertension	30 (60%)
Asthma	9 (18%)
Diabetes	5 (10%)
Symptoms	
Swelling in the anterior aspect of the neck	30 (60%)
Pain	10 (20%)
Hoarseness	8 (16%)
Dysphagia	8 (16%)
Duration of symptoms (months)	95 (1-180)
TIRADS Score	
TIRADS 1 (Benign)	1 (2%)
TIRADS 2 (Not suspicious)	1 (2%)
TIRADS 3 (Mildly suspicious)	9 (18%)
TIRADS 4 (Moderately suspicious)	10 (20%)
TIRADS 5 (Highly suspicious)	29 (58%)

Findings on Ultrasonography and Ultrasonography Predictors of Malignancy

The findings of the ultrasound investigation showed that the majority of the nodules (24, or 48%) were 2.1–4 cm in size. Ultrasound nodules were solid in 40/50 (80%) patients, cystic nodules in three patients (6%), and both solid and cystic nodules (mixed echoic) in 7 (14%) patients.

Ultrasound detected mixed vascularity in 28% of thyroid patients. Peripheral vascularity was found in 36% of patients.

Our result showed that solitary thyroid nodules appear (68%) on the right side of the thyroid, (30%) on the left side of the thyroid, and 1 (2%) are isthmic cases (Table 2).

Table (2): Comparison between nodules having a specified ultrasound characteristic and histologically proven benign nodules versus malignant nodules.

Ultrasound findings	(N = 50)
Echogenicity	
Solid	40 (80%)
Cystic	3 (6%)
Mixed	7 (14%)
Size (cm)	
<1	6 (12%)
1.0 - 2.0	11 (22%)
2.1 - 4.0	24 (48%)
>4.0	9 (18%)
Vascularity	
None	10 (20%)
Mixed	14 (28%)
Intra-nodular	8 (16%)
Peripheral	18 (36%)
Side	
Rt side Solitary Thyroid Nodule	34 (68%)
Lt side Solitary Thyroid Nodule	15 (30%)
Isthmic	1 (2%)

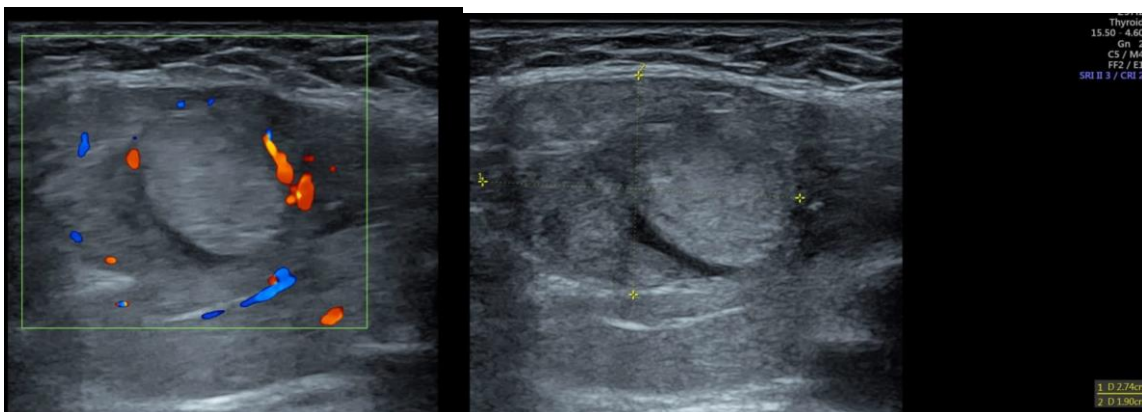


Figure (1): Isthmic

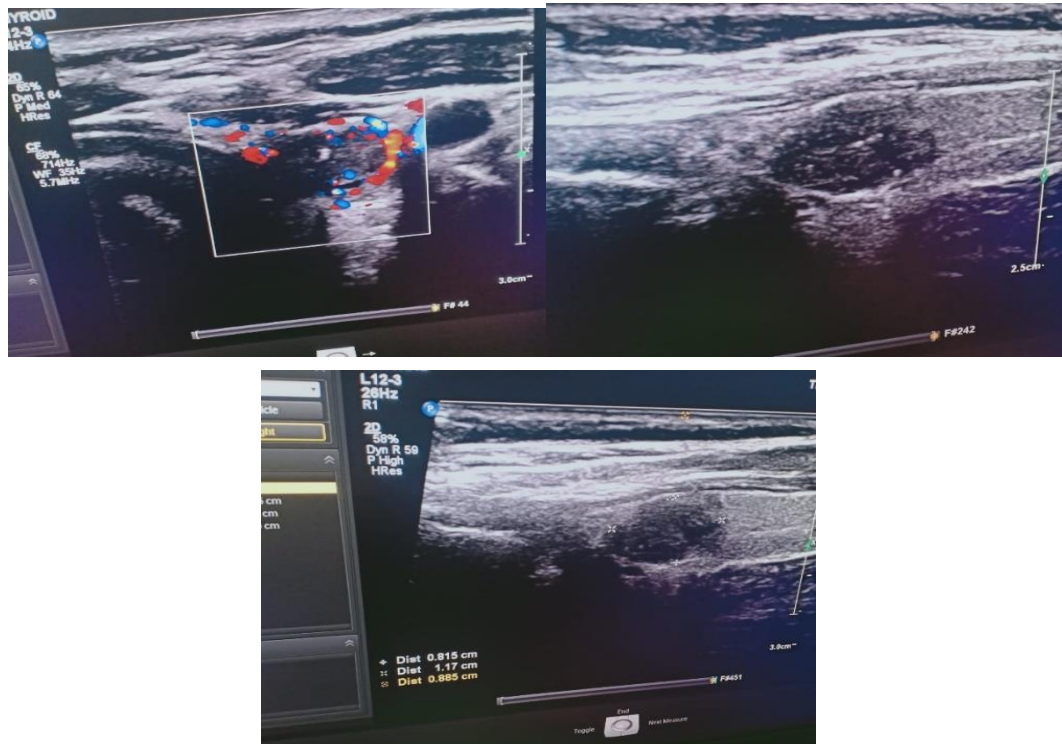


Figure (1): Left lobe thyroid hypoechoic nodule with irregular outlines and increased internal vascularity (TIRADS IV).

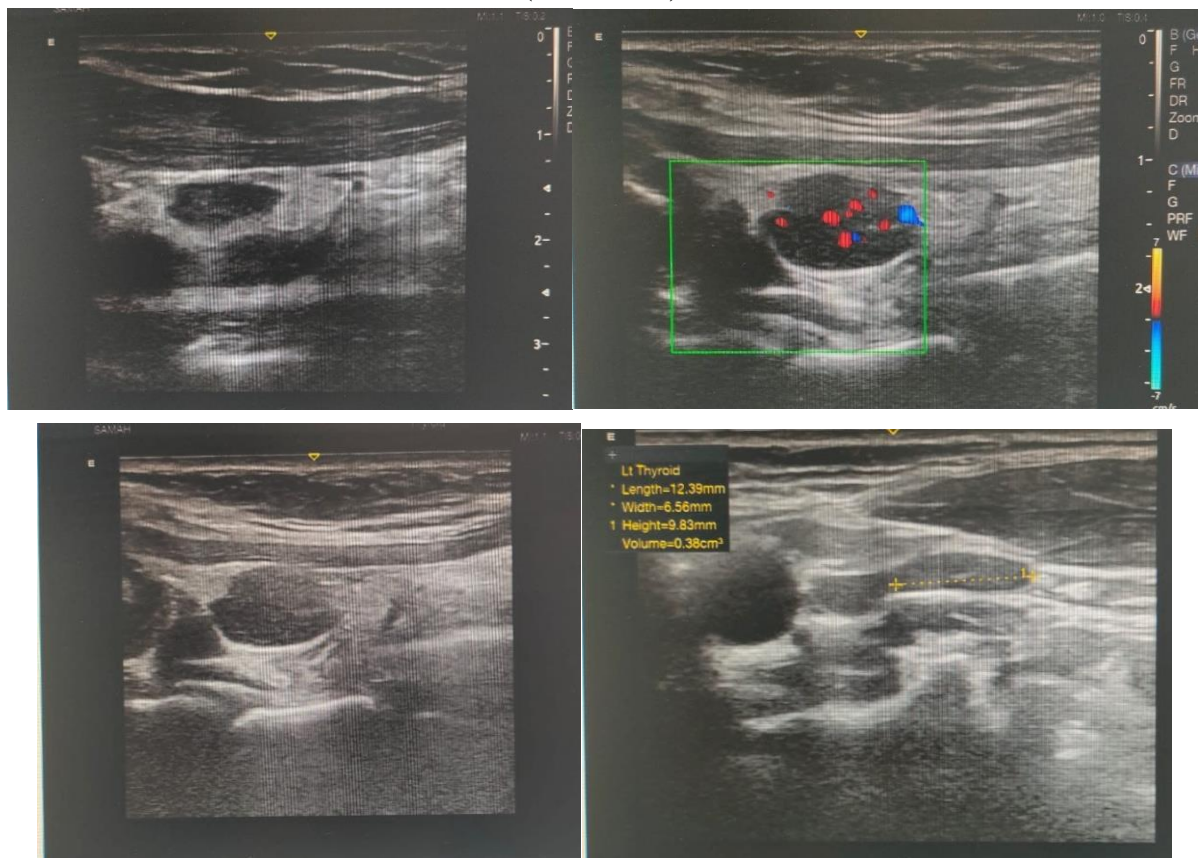


Figure (2): A single well defined solid idoechoic left lobe thyroid nodule measures about 30 x 20mm wider than taller with an irregular outline without extrathyroid extension, cystic changes inside, and no calcification (TIRAD 4).

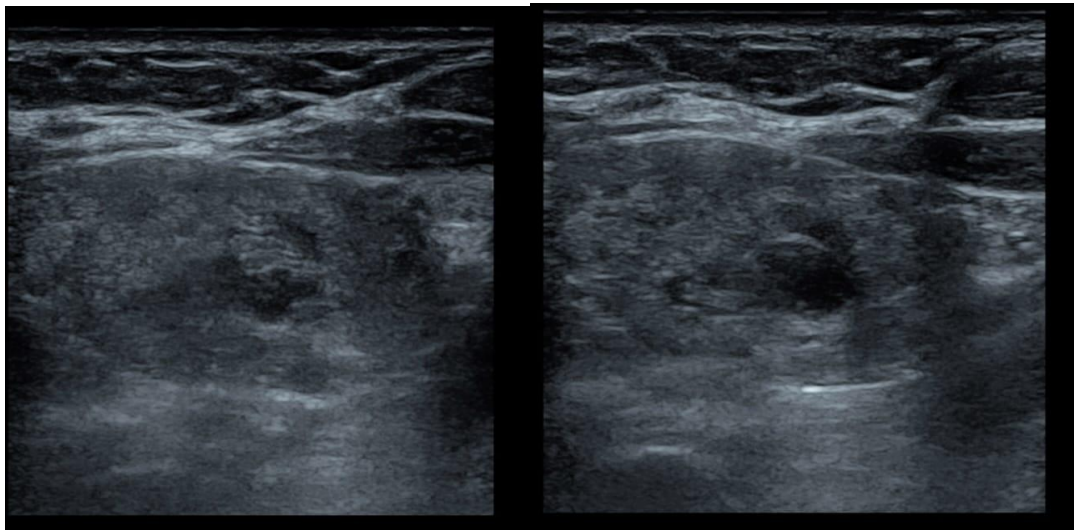


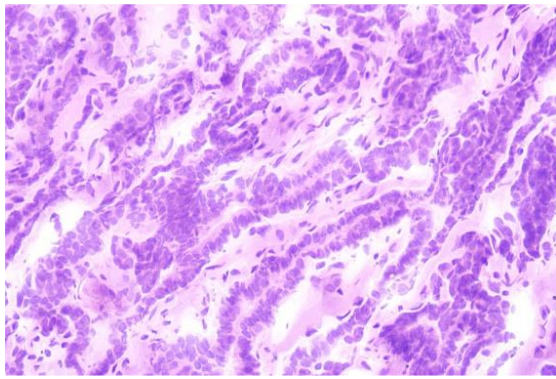
Figure (3):Left lobe hypoechoic thyroid nodule with internal calcifications (TIRAD IV). A single well defined solid with a cystic component in an inhomogenous isoechoic thyroid nodule involves the isthmus and measures about 27.4 x 19 mm wider than taller with a smooth outline without extrathyroid extension, few echogenic foci, and minute cystic changes inside the solid portion of the nodule (TIRAD 4).

FS analysis

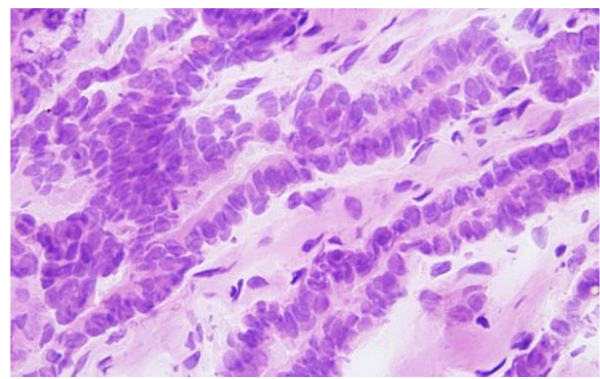
According to the frozen section, it was successfully performed on all 50 patients (Table 3). Thyroid nodules were malignant in 70% of patients: 56% were papillary and 14% had follicular malignant thyroid nodules. Five patients (10%) proved to be benign. Indeterminate nodules were detected in 20% of the studied cases in the final histological diagnosis.

Table (3): FS statistics

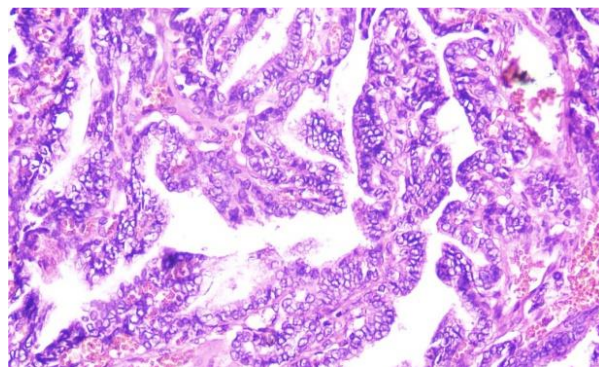
FS (n=50)	
Prevalence	70%
Malignant	35 (70%)
papillary,	28 (56%)
follicular	7 (14%)
Benign	5 (10%)
Others	10 (20%)
Hurthle cell neoplasm	5 (10%)
calcified thyroid nodule	3 (6%)
calcified colloid	2 (4%)



A



B



C

Figure (4): (A) Papillary thyroid carcinoma frozen section: papillary structures with fibrovascular cores covered by follicular cells with crowded, overlapped nuclei (100x). (B): Papillary thyroid carcinoma frozen section: papillary structures with fibrovascular cores covered by follicular cells with crowded, overlapped nuclei showing nuclear grooving (400x). (C, D): Papillary thyroid carcinoma paraffin section: papillary structures with fibrovascular cores covered by follicular cells with crowded, overlapped, optically clear nuclei showing nuclear grooving (200x).

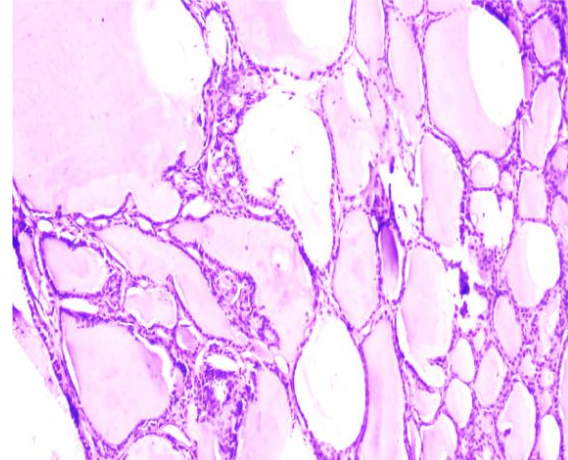
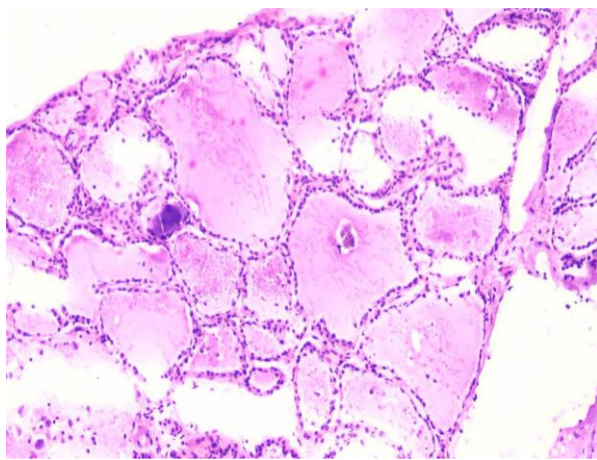


Figure (5): Adenomatous goitre frozen section showed variable-sized thyroid follicles lined by bland-looking follicular cells. The lumens of the follicles were dilated and filled with colloid (100x).

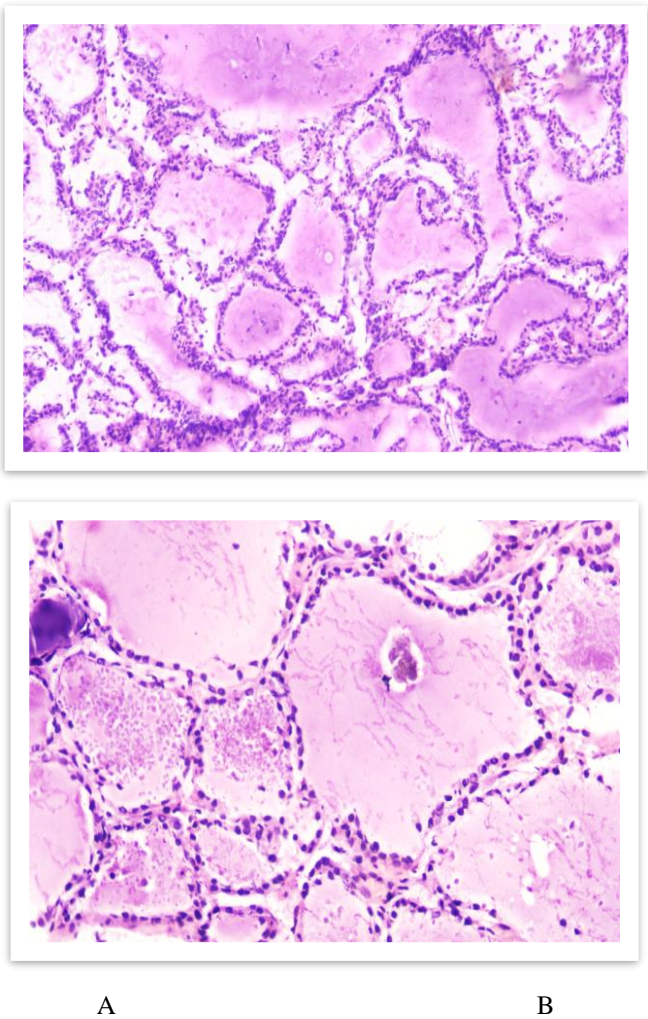


Figure (6) : (A): Adenomatous goitre frozen section: the section showed variable-sized thyroid follicles lined by bland-looking follicular cells. The lumens of follicles were dilated and filled with colloid (100x). (B): Adenomatous goitre paraffin section: the section showed variable-sized thyroid follicles lined by bland-looking follicular cells. The lumens of follicles were dilated and filled with colloid (200x).

The frozen section analysis showed a sensitivity of 67% compared to 89% in the ultrasound analysis. The specificity score showed that frozen section recorded 96.6% while ultrasound analysis recorded 93% (Table 4).

Table (4): PPV, NPV, Sensitivity, and Specificity of Ultrasound and Frozen Section

	Frozen section	Ultrasound
Negative predictive value (NPV) 95% CI	81% (78% to 98%)	83% (65% to 86%)
Positive predictive value (PPV) 95% CI	86% (56% to 99%)	80% (33% to 97%)
Specificity 95% CI	96.6% (86% to 99%)	67% (73% to 81%)
Sensitivity 95% CI	93% (42% to 90%)	89% (25% to 98%)

3. DISCUSSION

In order to distinguish benign thyroid nodules from malignant thyroid nodules, ultrasound requirements such as marked hypoechogenicities (15), hypoechogenicities (16, 17, 18, 19), irregular or microlobulated margins (15, 17, 18, 19, 20),

micro-calcifications (15, 17, 18, 19, 20, 21, 22), macro-calcifications (19), longer than wider in form (15, 17, 19), intranodule vascularities (18, 22, 23), and solidness (18, 20) are quite helpful. Based on its simplicity and excellent NPV (15, 17), the categorization developed by Kim et al. (15) was adopted in this investigation to classify solitary thyroid nodules as "positive" or "negative" in the US.

Whereas US characteristics can help distinguish between benign and malignant solitary thyroid nodules, they were used for a more thorough analysis and therapy. According to reports, US overall accuracy ranges from 90–95% to 100% in TC (24, 25, 26). Nevertheless, the US categories of "inadequate specimen," "suspicious for malignancy," or "follicular lesion," which do not include instructions for managing thyroid nodules, were not taken into consideration. Additionally, different institutions use different diagnostic terms for questionable outcomes (such as atypical, intermediate, or suspicious), which may confuse doctors (27). Up to 30% of thyroid nodules could be detected in the US as suspicious or ambiguous (26, 28). When follicular or Hurthle cell neoplasms were included, many researchers used the label "suspicious" (29, 30, 31, 32, 33). Other researchers (34) referred to follicular or Hurthle cellular neoplasms as "indeterminate." Differentiating it from the categorization of "indeterminate" or "suspicious," a few scholars have categorized and examined the designation "suspect for PTC" on US (16, 35, 36). In accordance with the recommendations made by the American Association of Clinical Endocrinologists and Associazione Medici Endocrinologi (AACE/AME), 20% of indeterminate cytology outcomes are discovered to be malignant at surgical treatment, and around 10% of US samples are categorised as suspicious or indeterminate when follicular and Hurthle cell neoplasms are included (37, 38, 39, 40). Furthermore, depending on the diagnostic criteria utilised, for instance, whether follicle neoplasms and Hurthle cell neoplasms are included, the malignancy incidence of nodules categorised as indeterminate or suspicious is estimated to range between 6.1 and 82% (29, 30, 35, 36). The classification of samples at our hospital was as follows: benign, suggestive of TC, indeterminate (follicular or Hurthle cell neoplasm), or malignant. When samples in this investigation had a variety of cytologic defects linked to cell carcinoma but did not meet the diagnostic criteria for carcinoma, the cytologic outcome of suspicious for PTC was indicated. Nuclear membrane abnormalities, nucleolar disorders, and aberrant nucleus-to-cytoplasm ratios were among the cytologic irregularities that were present (16). The final histology revealed that solitary thyroid cancer affected 35 (70%) of the 50 individuals whose nodules were classified as suspicious in the US. This conclusion is consistent with findings from earlier research that evaluated the US-FNAB categorization of "suspicious" (35).

For thyroid nodules identified in the US as potentially thyroid cancer (PTC)-positive, the ATA recommendations advise thyroid surgery. The ATA recommendations, though, do not specify the scope of thyroid surgery or intraoperative FS (28). The AACE/AME recommendations state that intraoperative FS must be done to assist in operational decision-making. Unfortunately, it frequently is not helpful in identifying benign from malignant thyroid nodules (37). The preoperative US is now supplemented with FS, which was once a crucial part of thyroid surgery (32). A few reports recommended routine FS because sensitivity and specificity are improved when consolidated US and FS are executed (41, 42). Unfortunately, despite US cytology, routine FS is not advised in several recent studies, and intraoperative FS is only helpful in cases when cytology is insufficient or the US is classified as "suspicious for malignancy" (29, 32, 43, 44). A few investigations (16, 36) have shown that thyroid nodules cytologically suspected of having TC can benefit from US or FS. In order to generate a management framework, including the degree of thyroid surgery needed in nodules classified as suspicious for TC on US, we looked into the joint involvement of US and FS. According to this research, the malignancy incidence was 70% when the thyroid nodules were positive on US and suspected for TC on US, which is comparable to the malignancy incidence seen when PTC or malignancy were diagnosed on US (29, 35, 36). On the other hand, as per the TIRADS Score, 64% of patients were mildly suspicious, 22% were moderately suspicious, and 14% of cases were highly suspicious thyroid nodules. Of these, thyroid cancer was discovered in 25 out of 50 (50%) of the individuals with thyroid cancer on FS. FS is not required when a thyroid nodule is positive on US and shows signs of TC. On the contrary, FS is required to prevent a complete thyroidectomy when a thyroid nodule is negative on ultrasound but suggestive of TC on ultrasound.

4. LIMITATIONS

The investigation has its drawbacks. Primarily, only individuals who had undergone thyroid surgery, US and intraoperative FS, or both, were involved in this prospective analysis. Additionally, 50 patients with suspected TC on US were also considered. Selection bias could not have been entirely prevented as a result. Secondly, cytology slides were analysed by five cytopathologists, and interobserver variation can occur when determining if a nodule is suspicious for TC. Last but not least, this research could not be replicated in other institutions because it is dependent on evaluation data collected by thyroid experts.

5. CONCLUSION

To conclude, we can depend on the US alone as a predictable tool for malignant solitary thyroid nodules to perform thyroidectomy operations. On the other hand, FS may assist surgeons in deciding the degree of surgery for thyroid nodules that have US readings suspicious for TC but no worrisome malignant characteristics in the absence of FS.

6. RECOMMENDATIONS

Further studies with an increase in the number of patients and more centres are needed to detect accurate results. At the end of the study, we can say that it depends on US for the decision for total thyroidectomy in suspicious solitary thyroid nodules in the absence of FZ.

REFERENCES

- [1] Tabet P, Saydy N, Letourneau-Guillon L, Gologan O, Bissada É, Ayad T, et al. Cystic masses of the lateral neck: diagnostic value comparison between fine-needle aspiration, core-needle biopsy, and frozen section. *Head & Neck*. 2019;41(8):2696-703.
- [2] AbdRabo AA, Mahfouz MF, Darwish AA, Ammar AYA. The Evaluation of Routine Central Nodal Dissection in Radiologically Node Negative Differentiated Thyroid Carcinoma. *The Egyptian Journal of Hospital Medicine*. 2018;73(1):5709-14.
- [3] Damayanthi BS, Chandraiah KR. Thyroid Lesions Classification Using Bethesda System with Histopathological Correlation And Calculating Each Category Malignancy Risk. *Indian Journal of Pathology: Research and Practice*. 2018;7(8):893.
- [4] Monib S, Farkas N, Abdelaziz MI. A prospective observational study assessing the relationship between solitary thyroid nodule size and incidence of malignancy. *Cureus*. 2020;12(11).
- [5] Papini E, Monpeyssen H, Frasoldati A, Hegedüs L. 2020 European thyroid association clinical practice guideline for the use of image-guided ablation in benign thyroid nodules. *European thyroid journal*. 2020;9(4):172-85.
- [6] Teng D-K, Li W-H, Du J-R, Wang H, Yang D-Y, Wu X-L. Effects of microwave ablation on papillary thyroid microcarcinoma: a five-year follow-up report. *Thyroid*. 2020;30(12):1752-8.
- [7] Nambron R, Rosenthal R, Bahl D. Diagnosis and evaluation of thyroid nodules-the clinician's perspective. *Radiologic Clinics*. 2020;58(6):1009-18.
- [8] Erkinuresin T, Demirci H. Diagnostic accuracy of fine needle aspiration cytology of thyroid nodules. *Diagnosis*. 2020;7(1):61-6.
- [9] Cao X-J, Wang S-R, Che Y, Liu J, Cong Z-B, He J-F, et al. Efficacy and safety of thermal ablation for treatment of solitary T1N0M0 papillary thyroid carcinoma: a multicenter retrospective study. *Radiology*. 2021;300(1):209-16.
- [10] Jie SCS, Tan CC. A rare case of primary tuberculosis in a solitary thyroid nodule. *Indian Journal of Tuberculosis*. 2020;67(3):360-2.
- [11] Harshvardhan R, Jorwal V, Gupta S, Sharma V, Sehra R, Agarwal S. Assessment of Accuracy of Fine Needle Aspiration Cytology and Ultrasonography in Relation to Histopathology in Cases of Solitary Thyroid Nodule. *Indian Journal of Otolaryngology and Head & Neck Surgery*. 2020:1-8.
- [12] Lakshmi YA, Reddy KN. A clinicopathological evaluation of solitary nodule in thyroid; a retrospective observational hospital based study. *International Surgery Journal*. 2020;7(12):3951-4.
- [13] Kant R, Davis A, Verma V. Thyroid nodules: advances in evaluation and management. *American Family Physician*. 2020;102(5):298-304.
- [14] Brooks AD, Shaha AR, DuMornay W, Huvos AG, Zakowski M, Brennan MF, et al. Role of fine-needle aspiration biopsy and frozen section analysis in the surgical management of thyroid tumors. *Annals of surgical oncology*. 2001;8:92-100.
- [15] Kim E-K, Park CS, Chung WY, Oh KK, Kim DI, Lee JT, et al. New sonographic criteria for recommending fine-needle aspiration biopsy of nonpalpable solid nodules of the thyroid. *American Journal of Roentgenology*. 2002;178(3):687-91.
- [16] Kwak JY, Kim E-K, Kim MJ, Hong SW, Choi SH, Son EJ, et al. The role of ultrasound in thyroid nodules with a cytology reading of "suspicious for papillary thyroid carcinoma". *Thyroid*. 2008;18(5):517-22.
- [17] Tae HJ, Lim DJ, Baek KH, Park WC, Lee YS, Choi JE, et al. Diagnostic value of ultrasonography to distinguish between benign and malignant lesions in the management of thyroid nodules. *Thyroid*. 2007;17(5):461-6.
- [18] Frates MC, Benson CB, Charboneau JW, Cibas ES, Clark OH, Coleman BG, et al. Management of thyroid nodules detected at US: Society of Radiologists in Ultrasound consensus conference statement. *Radiology*. 2005;237(3):794-800.
- [19] Moon W-J, Jung SL, Lee JH, Na DG, Baek J-H, Lee YH, et al. Benign and malignant thyroid nodules: US differentiation-multicenter retrospective study. *Radiology*. 2008;247(3):762.

- [20] Peccin S, De Castro J, Furlanetto TW, Furtado A, Brasil B, Czepielewski M. Ultrasonography: is it useful in the diagnosis of cancer in thyroid nodules? *Journal of endocrinological investigation*. 2002;25(1):39-43.
- [21] Khoo ML, Asa SL, Witterick IJ, Freeman JL. Thyroid calcification and its association with thyroid carcinoma. *Head & Neck: Journal for the Sciences and Specialties of the Head and Neck*. 2002;24(7):651-5.
- [22] Papini E, Guglielmi R, Bianchini A, Crescenzi A, Taccogna S, Nardi F, et al. Risk of malignancy in nonpalpable thyroid nodules: predictive value of ultrasound and color-Doppler features. *The Journal of Clinical Endocrinology & Metabolism*. 2002;87(5):1941-6.
- [23] Frates MC, Benson CB, Doubilet PM, Cibas ES, Marqusee E. Can color Doppler sonography aid in the prediction of malignancy of thyroid nodules? *Journal of ultrasound in medicine*. 2003;22(2):127-31.
- [24] Bugis SP, Young JEM, Archibald SD, Chen VS. Diagnostic accuracy of fine-needle aspiration biopsy versus frozen section in solitary thyroid nodules. *The American journal of surgery*. 1986;152(4):411-6.
- [25] Gharib H, editor *Fine-needle aspiration biopsy of thyroid nodules: advantages, limitations, and effect*. Mayo Clinic Proceedings; 1994: Elsevier.
- [26] Gharib H, Goellner JR. Fine-needle aspiration biopsy of the thyroid: an appraisal. *Annals of internal medicine*. 1993;118(4):282-9.
- [27] Redman R, Yoder BJ, Massoll NA. Perceptions of diagnostic terminology and cytopathologic reporting of fine-needle aspiration biopsies of thyroid nodules: a survey of clinicians and pathologists. *Thyroid*. 2006;16(10):1003-8.
- [28] Cooper DS, Doherty GM, Haugen BR, Kloos RT, Lee SL, Mandel SJ, et al. Management guidelines for patients with thyroid nodules and differentiated thyroid cancer: The American Thyroid Association Guidelines Taskforce. *Thyroid*. 2006;16(2):109-42.
- [29] Brooks AD, Shaha AR, DuMornay W, Huvos AG, Zakowski M, Brennan MF, et al. Role of fine-needle aspiration biopsy and frozen section analysis in the surgical management of thyroid tumors. *Annals of surgical oncology*. 2001;8(2):92-100.
- [30] Chao T-C, Lin J-D, Chao H-H, Hsueh C, Chen M-F. Surgical treatment of solitary thyroid nodules via fine-needle aspiration biopsy and frozen-section analysis. *Annals of Surgical Oncology*. 2007;14(2):712-8.
- [31] De Vos Tot Nederveen Cappel R, Bouvy N, Bonjer H, Van Muiswinkel J, Chadha S. Fine needle aspiration cytology of thyroid nodules: how accurate is it and what are the causes of discrepant cases? *Cytopathology*. 2001;12(6):399-405.
- [32] Richards ML, Chisholm R, Bruder JM, Strodel WE. Is thyroid frozen section too much for too little? *The American journal of surgery*. 2002;184(6):510-4.
- [33] Sangalli G, Serio G, Zampatti C, Bellotti M, Lomuscio G. Fine needle aspiration cytology of the thyroid: a comparison of 5469 cytological and final histological diagnoses. *Cytopathology*. 2006;17(5):245-50.
- [34] Sclabas GM, Staerckel GA, Shapiro SE, Fornage BD, Sherman SI, Vassilopoulos-Sellin R, et al. Fine-needle aspiration of the thyroid and correlation with histopathology in a contemporary series of 240 patients. *The American Journal of Surgery*. 2003;186(6):702-10.
- [35] Basolo F, Ugolini C, Proietti A, Iacconi P, Berti P, Miccoli P. Role of frozen section associated with intraoperative cytology in comparison to FNA and FS alone in the management of thyroid nodules. *European Journal of Surgical Oncology (EJSO)*. 2007;33(6):769-75.
- [36] Haymart MR, Greenblatt DY, Elson DF, Chen H. The role of intraoperative frozen section if suspicious for papillary thyroid cancer. *Thyroid*. 2008;18(4):419-23.
- [37] Gharib H, Papini E, Paschke R, Duick DS, Valcavi R, Hegedus L. Medical guidelines for clinical practice for the diagnosis and management of thyroid nodules. *Endocr Pract*. 2006;12(1):63-102.
- [38] Castro MR, Gharib H. Thyroid fine-needle aspiration biopsy: progress, practice, and pitfalls. *Endocrine practice*. 2003;9(2):128-36.
- [39] Castro MR, Gharib H. Continuing controversies in the management of thyroid nodules. *Annals of internal medicine*. 2005;142(11):926-31.
- [40] CERSOSIMO E, GHARIB H, SUMAN VJ, GOELLNER JR, editors. "Suspicious" thyroid cytologic findings: outcome in patients without immediate surgical treatment. *Mayo Clinic Proceedings*; 1993: Elsevier.
- [41] Chang H-Y, Lin J-D, Chen J-F, Huang B-Y, Hsueh C, Jeng L-B, et al. Correlation of fine needle aspiration cytology and frozen section biopsies in the diagnosis of thyroid nodules. *Journal of Clinical Pathology*. 1997;50(12):1005-9.
- [42] Paphavasit A, Thompson GB, Hay ID, Grant CS, van Heerden JA, Ilstrup DM, et al. Follicular and Hürthle

cell thyroid neoplasms: is frozen-section evaluation worthwhile? *Archives of Surgery*. 1997;132(6):674-9.

- [43] Huber GF, Dziegielewski P, Matthews TW, Warshawski SJ, Kmet LM, Faris P, et al. Intraoperative frozen-section analysis for thyroid nodules: a step toward clarity or confusion? *Archives of Otolaryngology–Head & Neck Surgery*. 2007;133(9):874-81.
- [44] Olson S, Cheema Y, Harter J, Starling J, Chen H. Does frozen section alter surgical management of multinodular thyroid disease? *Journal of Surgical Research*. 2006;136(2):179-81