

Demographic Study of Inguino-Scrotal Swellings and Outcome of Their Management in Pediatric Age Group at GMC Ratlam

Dr. Vikram Singh Mujalde¹, Dr. Sardar Gautham Singh², Dr. Nandini Baldawa³, Dr. Narmada Mandela⁴, Dr. Neelam R. Charles⁵

¹Associate Professor, ²³⁴PG Residents, ⁵Professor & Head, Department of Surgery, Government Medical College, Ratlam (M.P.), India

ABSTRACT

Background: Inguino-scrotal swellings are among the most common pediatric surgical problems, including hernia, hydrocele, and undescended testes. Objective: To study the demographic pattern and outcomes of management of pediatric inguino-scrotal swellings at a tertiary center in central India.

Methods: A prospective observational study was conducted on 90 pediatric patients (<17 years) admitted with inguino-scrotal swellings in GMC Ratlam over 18 months. Demographic details, diagnosis, surgical approach, and postoperative outcomes were analyzed.

Results: Male predominance was observed (92.2%). The most common diagnosis was right inguinal hernia (33%), followed by left hernia (19%) and hydrocele (8%). Open herniotomy was performed in 55 (61%) and laparoscopic repair in 25 (27%) cases. 93% underwent elective surgery. Postoperative complications were minimal (6.6%), mostly wound discharge.

Conclusion: Pediatric inguino-scrotal swellings are predominantly hernias in males with excellent outcomes following timely surgical intervention. Laparoscopy offers safe and cosmetically superior results.

Keywords: Pediatric surgery, inguinal hernia, hydrocele, orchidopexy, herniotomy

How to Cite: Dr. Vikram Singh Mujalde, Dr. Sardar Gautham Singh, Dr. Nandini Baldawa, Dr. Narmada Mandela, Dr. Neelam R. Charles, (2025) Demographic Study of Inguino-Scrotal Swellings and Outcome of Their Management in Pediatric Age Group at GMC Ratlam, *Journal of Carcinogenesis*, Vol.24, No.9s, 565-568.

1. INTRODUCTION

Inguino-scrotal swellings represent one of the most frequent surgical presentations in children worldwide. They primarily include inguinal hernia, hydrocele, and undescended testes, each arising due to abnormal closure of the processus vaginalis during fetal development. The reported incidence of inguinal hernia in children ranges between **0.8–4.4%**, equivalent to approximately 10–20 per 1000 live births.^{1,2}

The condition shows a striking **male predominance** and is more frequent on the **right side**. In most cases, parents observe the swelling during crying or straining. Hernias in children are **indirect, congenital**, and caused by a patent processus vaginalis, while hydroceles represent fluid accumulation in the tunica vaginalis.^{3,4,5}

Early surgical correction is essential to prevent complications such as **incarceration and strangulation**. Undescended testes (cryptorchidism) often coexist with hernias, warranting **orchidopexy** for anatomical correction and fertility preservation.⁶

Despite the established surgical approach, there remains variation in demographic distribution and management outcomes across regions, particularly in rural India. This study aims to delineate the **demographic profile, clinical spectrum, and surgical outcomes** of inguino-scrotal swellings in the pediatric age group managed at **Government Medical College, Ratlam**, a tertiary care institution serving a predominantly rural population.

2. MATERIALS AND METHODS

A prospective observational study was conducted in the Department of General Surgery, Government Medical College, Ratlam, over 18 months. All patients below 17 years presenting with inguino-scrotal swellings were included after consent. **Exclusion criteria** included patients unwilling to participate and those with acute scrotal conditions (epididymo-orchitis, torsion, funiculitis).

Data Collection: Demographic details, diagnosis, laterality, surgical procedure, and postoperative outcomes were recorded using a standardized pro forma.

Surgical Techniques: Patients underwent either **open herniotomy** or **laparoscopic repair** depending on presentation and surgeon preference. Hydroceles and undescended testes were managed by **eversion of sac** and **orchidopexy**, respectively.

Data Analysis: Statistical analysis was performed using Microsoft Excel. Frequency, percentage, and distribution were calculated for all parameters.

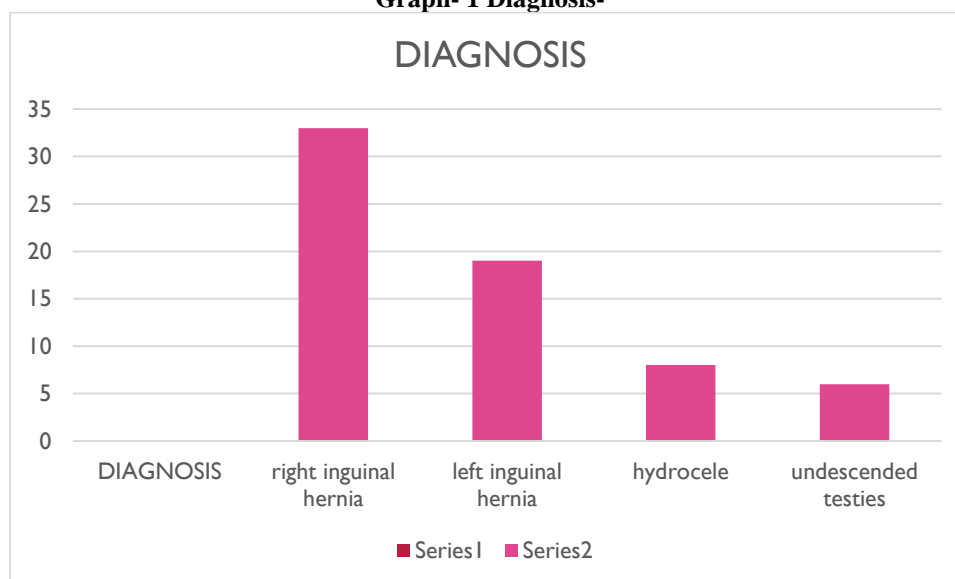
Ethical Clearance: The study was approved by the **Institutional Ethics Committee (IEC)**, **Dr. L.N. Government medical college Ratlam**.

3. RESULTS

A total of **90 pediatric patients** were included.

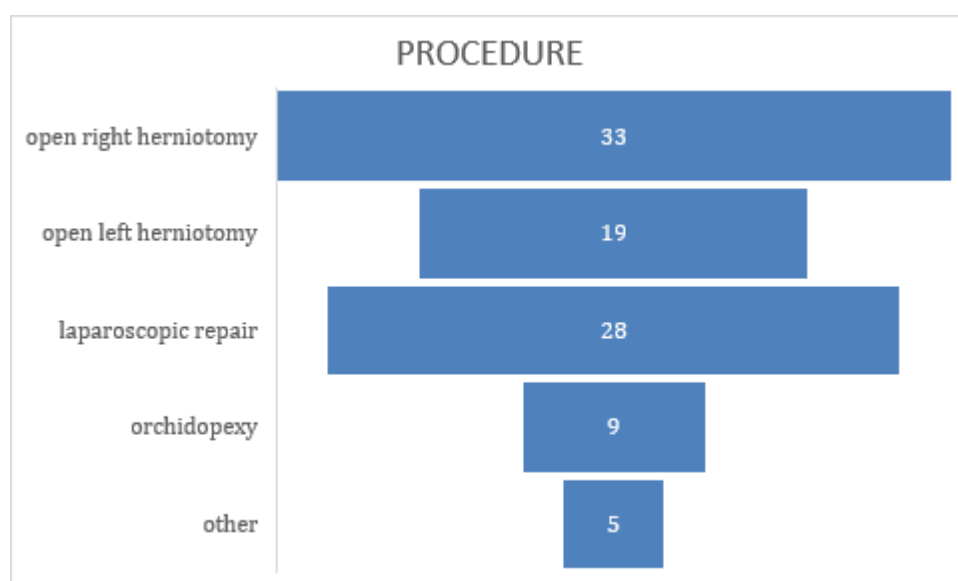
- **Sex distribution:** 83 males (92.2%), 7 females (7.8%).
- **Common diagnoses:** Right inguinal hernia (33%), left inguinal hernia (19%), hydrocele (8%), undescended testes (6%).

Graph- 1 Diagnosis-



- **Laterality:** 84% unilateral, 16% bilateral.
- **Nature of surgery:** 84 elective, 6 emergency.
- **Procedures performed:**
 - Open right herniotomy – 30 cases (33%)
 - Open left herniotomy – 17 cases (19%)
 - Laparoscopic repairs (various) – 25 cases (28%)
 - Orchidopexy – 7 cases
 - Miscellaneous (abscess drainage, debridement, orchidectomy) – <5%

GRAPH NO- 2 PROCEDURE



Postoperative outcomes:

- 93% had uneventful recovery.
- 6.6% developed minor wound complications (infection/discharge).
- No recurrence, mortality, or major complications were recorded.

Mean hospital stay: 1–3 days for uncomplicated cases.

Laparoscopic repairs had slightly shorter discharge duration and superior cosmetic outcome.

4. DISCUSSION

The study reaffirms that **inguinal hernia and hydrocele** constitute the majority of pediatric inguino-scrotal swellings. The overwhelming **male preponderance (92%)** aligns with earlier studies by Koranga et al. (2018) and Suvera et al. (2021), reflecting the embryological persistence of the processus vaginalis predominantly in males.

The **right-sided predominance** observed in our series corresponds with known anatomical delay in testicular descent on the right side. **Open herniotomy** remains the gold standard, especially in resource-limited settings, though **laparoscopic repairs** are increasingly performed, offering superior visualization and the ability to assess the contralateral ring.

The **low complication rate (6.6%)** and absence of recurrence highlight the safety and efficacy of both open and laparoscopic techniques in children. The average hospital stay of **1–3 days** supports the practice of **day-care or short-stay surgery**, consistent with Shah et al. (2010).

The presence of **associated anomalies** such as undescended testes emphasizes the need for thorough evaluation and simultaneous correction during hernia surgery.

This study provides valuable regional data from a rural tertiary institution, reinforcing that with timely diagnosis and appropriate surgical intervention, **pediatric inguino-scrotal conditions have excellent outcomes** with minimal morbidity.

5. CONCLUSION

Inguino-scrotal swellings in the pediatric population are predominantly **congenital hernias and hydroceles** with marked **male predominance**. Early diagnosis and surgical management, whether open or laparoscopic, ensure excellent outcomes and low complication rates. Laparoscopy is increasingly becoming a preferred option due to its diagnostic and cosmetic advantages. Public awareness and prompt referral can further improve outcomes in rural settings like Ratlam.

REFERENCES

- [1] Koranga H, Chandrasekaran R. Int Surg J 2018;5:2097–102.
- [2] Wani DI, Prabhakar A, Sharma S, Nafees R. Int J Res Med Sci 2020;8:3235–8.
- [3] Suvera M, Chaudhari P, Patel S. Int Surg J 2021;8:3335–8.
- [4] Wani AH, et al. Int J Life Sci Biotechnol Pharma Res 2023.

- [5] Brainwood M, Beirne G, Fenech M. *Australas J Ultrasound Med* 2020;23(1):22–9.
 - [6] Shrestha D, et al. *Med J Pokhara Acad Health Sci* 2019;3(2):45–51.
 - [7] Erikci VS, et al. *Ulus Travma Acil Cerrahi Derg* 2013;19(4):333–6.
 - [8] Shah JN, Subedi N. *J Nep Paedtr Soc* 2010;30(3):128–31.
 - [9] Verma R, et al. *Int J Sci Stud* 2018;6(5):1–5.
 - [10] Townsend CM Jr., et al. *Sabiston Textbook of Surgery*. 18th ed. Elsevier; 2007.
 - [11] Agrawal L, et al. *Med J DY Patil Vidyapeeth* 2023;16:197–202.
 - [12] Bašković M, et al. *World J Pediatr Surg* 2022;5(4):e000461.
-