

Access this article online

Quick Response Code:



Website:

www.carcinogenesis.com

DOI:

10.4103/jcar.JCar_27_20

Clinical diagnostic criteria versus advanced imaging in prediction of cervical lymph node metastasis in oral squamous cell carcinomas: A magnetic resonance imaging based study

F. Lalfamkima, G. L. Georgeno¹, N. Koteswara Rao², Rajkumar Selvakumar³,
Vimal Joseph Devadoss¹, Niroshini Rajaram⁴, Shomaila Farid⁵,
T. Lalchhuanawma, Abhishek Singh Nayyar⁶

Consultant Dental Surgeon, Selection Grade, Dental Department, Civil Hospital, Aizawl, Mizoram,
²Department of Oral and Maxillofacial Surgery, Drs Sudha and Nageswara Rao Siddhartha Institute of Dental Sciences, Chinoutpalli, Gannavaram Mandal, Krishna District, Andhra Pradesh,
³Department of Oral Medicine and Radiology, Saraswati Dhanwantari Dental College and Hospital and Post-graduate Research Institute, Parbhani, Maharashtra, ⁴Department of Oral and Maxillofacial Surgery, Rajas Dental College and Hospital, Kavalkinaru, Tirunelveli,
⁵Department of Oral and Maxillofacial Surgery, Rajah Muthiah Dental College and Hospital, Annamalai University, Annamalai Nagar, Cuddalore, ⁶Department of Oral Pathology and Microbiology, RVS Dental College and Hospital, Sulur, Coimbatore, Tamil Nadu, India, ⁵Consultant, Division of Infection Prevention and Control, Infection Control Department, Security Forces Specialized Health Center, Taif, Kingdom of Saudi Arabia

Address for correspondence:

Dr. T. Lalchhuanawma,
Consultant Dental Surgeon, Selection Grade,
Dental Department,
Civil Hospital, Aizawl,
Mizoram, India.
E-mail: ltchhong50@gmail.com

Submitted: 04-Dec-2020

Revised: 02-Feb-2021

Accepted: 19-Feb-2021

Published: 13-Apr-2021

Abstract:

CONTEXT AND AIM: The inaccuracies in clinical examination have been well documented, while advanced imaging modalities, including computed tomography and magnetic resonance imaging (MRI), have been shown to have superior diagnostic accuracy in detecting occult and nodal metastasis. The aim of the present study was to identify as well as evaluate the inaccuracies in clinical examination and of clinical diagnostic criteria in known cases of oral squamous cell carcinomas (OSCCs) with the help of MRI.

MATERIALS AND METHODS: A total of 24 patients attending as outpatients were included in the study, while clinically diagnosed and histopathologically proven cases of OSCC were examined clinically and then subjected to advanced imaging with the help of MRI.

STATISTICAL ANALYSIS USED: Statistical analysis was done using Statistical Package for the Social Sciences (SPSS) version 17.0 (SPSS Inc., Chicago, IL, USA), while paired *t*-test was performed for evaluating the size of tumor and lymph node recorded on clinical and imaging findings. A *P* < 0.05 was considered statistically significant.

RESULTS: Detection of tumor size and lymph node metastasis was found to be higher in case of MRI than when accomplished by clinical staging alone, while paired *t*-test values for difference in results were found to be statistically significant (*P* < 0.05).

CONCLUSIONS: The present study showed that clinical diagnostic criteria alone were not sufficient and reliable for detecting metastatic lymphadenopathy, highlighting the significance of advanced imaging modalities such as MRI for an efficient preoperative diagnostic workup, as well a tool for planning treatment in patients with OSCCs.

Keywords:

Magnetic resonance imaging, metastasis, multimodal imaging, oral squamous cell carcinoma

Introduction

Oral squamous cell carcinoma (OSCC) is the sixth most common cause of cancer-related deaths worldwide.^[1] In the Indian scenario, oral

cancer is the second most common cancer related to deaths.^[2] The presence of metastatic cervical lymphadenopathy is of particular importance, as with every single nodal metastasis, survival of the patient is reduced by half.^[3] Thus, regional metastasis is one

This is an open access journal, and articles are distributed under the terms of the Creative Commons Attribution-NonCommercial-ShareAlike 4.0 License, which allows others to remix, tweak, and build upon the work non-commercially, as long as appropriate credit is given and the new creations are licensed under the identical terms.

For reprints contact: WKHLRPMedknow_reprints@wolterskluwer.com

How to cite this article: Lalfamkima F, Georgeno GL, Rao NK, Selvakumar R, Devadoss VJ, Rajaram N, et al. Clinical diagnostic criteria versus advanced imaging in prediction of cervical lymph node metastasis in oral squamous cell carcinomas: A magnetic resonance imaging based study. J Carcinog 2021;20:3.

of the most important factors in deciding for prognosis and planning treatment in patients with OSCCs.^[4-6] The inaccuracies in clinical examination have, also, been well documented, while advanced imaging modalities including computed tomography (CT) and magnetic resonance imaging (MRI) have been shown to have superior diagnostic accuracy in detecting occult and nodal metastasis.^[7-11] Most commonly used tumor (T), node (N), and metastasis (M) classification (TNM classification) system fails to define the exact size and measurements of tumor including diameter, length, width, area, volume, and tumor thickness as well as clinical issues related to it.^[12,13] An appropriate management of OSCC cases requires a thorough understanding of factors affecting incidence, patterns, and prognostic implications of nodal metastasis.^[6] Identification of such prognostic factors could constitute one of the important keys to reduce mortality, morbidity, and most importantly, the recurrences in treated patients. The prognosis of patients with OSCCs that are treated early, in initial phases of malignancy, is found to be better because cure is achieved with less complex and lesser aggressive measures than what is obtainable in case of lesions that have reached advanced stages or metastases. Despite higher incidence and also higher mortality rates reported from India, no study describing diagnostic accuracy of important prognostic factors such as tumor thickness related to lymph nodal metastasis using modern imaging techniques has been documented.^[14] Furthermore, a number of studies have identified that among all aspects of tumor size studied, tumor thickness can be an important indicator in prediction of nodal metastasis as well as local recurrences and survival in patients with OSCC.^[15-19] Several such studies have been conducted on postoperative, resected specimens, while there are very few studies reported which were conducted preoperatively. Further complicating this situation is the observation that tumor size involving different areas has been found to affect different levels of lymph nodes and thereby controls survival in a varied manner.^[4,5] Hence, an accurate preoperative assessment of tumor size, in its all possible dimensions, becomes an essential component in optimizing treatment algorithm.^[20] MRI is a powerful imaging tool for cross-sectional analysis of head and neck. This is, especially, true with regard to oropharyngeal neoplasms wherein soft tissue spread, nodal disease, peri-neural invasions, and osseous involvement significantly alter treatment plan and prognosis.^[20,21] The aim of the present study was to identify as well as evaluate the inaccuracies in clinical examination and of clinical diagnostic criteria in known cases of OSCCs with the help of MRI.

Materials and Methods

A total of 24 patients including 11 patients with OSCC involving alveolus, six patients with OSCC involving

tongue, and seven patients with OSCC involving buccal mucosa attending as outpatients were included in the study, while clinically diagnosed and histopathologically proven cases of OSCC were examined clinically and then subjected to advanced imaging with the help of MRI [Figure 1]. Patients with known systemic diseases, those who had received any previous treatment in the form of radiotherapy, surgery, or chemotherapy, those with known contraindications to MRI including patients with cardiac pacemaker, cochlear implants, and ocular and dental implants, and patients in whom gadolinium-based contrast agents were contraindicated were excluded. The study protocol was approved by the Institutional Ethics Committee via letter approval no. SDDC/IEC/07-39-2018, while written, informed consent was obtained from all patients who participated in study. All patients were, then, subjected to routine blood investigations, fine-needle aspiration cytology (FNAC) of the ipsilateral submandibular lymph node (Level I), and incisional biopsy of oral lesion to confirm the diagnosis. As part of pre-diagnostic workup, a thorough clinical examination was performed, while details were recorded in a specially devised pro forma. Complete lymph nodal examination was carried out. The armamentarium used for MRI examination included 1.5 Tesla Magnetom Avanto Systems (Siemens, Germany). All patients were asked to fast for 6 h before MRI examination, while specific sequences were obtained including axial T1-weighted, spin-echo images from face and neck region including maxilla and mandible wherein localizer was widened in cases of larger fields (TR/TE: 400–640 ms/10–14 ms; slice thickness: 4–7 mm; gap: 1–2 mm; field of view: 24–38 cm; NEX: 1–2; matrix: 256 × 192–256). Followed by this, axial T2-weighted, fast spin-echo images of the face and neck (TR/TE: 4000–6000 ms/90–110 ms; echo-train length: 8; slice thickness: 4–7 mm; gap: 1–2 mm; field of view: 24–38 cm; NEX: 2; matrix: 512 × 256), sagittal T2-weighted, fast spin-echo images from canthomeatal line to supraclavicular level

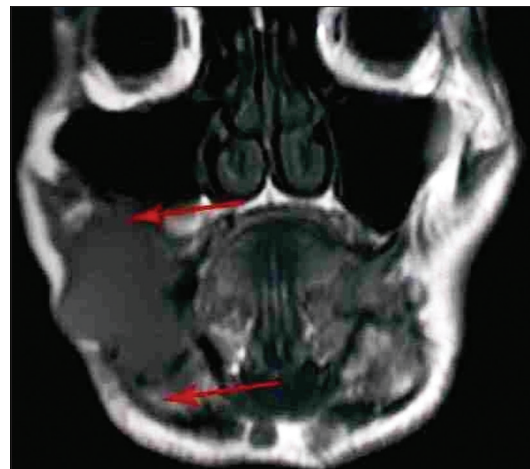


Figure 1: Magnetic resonance imaging image of a patient (coronal view)

(TR/TE: 4000–6000 ms/90–110 ms; echo-train length: 8; slice thickness: 4–7 mm; gap: 1–2 mm; field of view: 24–32 cm, NEX: 2; matrix: 512 × 256), and unenhanced and enhanced fat-suppressed, coronal T1-weighted images (TR/TE: 126 ms/2.47 ms; flip angle: 70°; slice thickness: 4–7 mm; gap: 1–2 mm; field of view 30–36 cm; NEX: 2–4; matrix: 256 × 192–256; spectral fat suppression) were obtained. Contrast-enhanced images were obtained after intravenous injection of 0.1 mmol/kg body weight of gadobenate dimeglumine (Multihance; Bracco, Milan, Italy). Postcontrast images were obtained in two planes. Additional sequences were, also, taken in few patients as per the requirement while doing procedure. With the help of these sequences, tumor size was assessed in terms of diameter, length, width, area, volume, and tumor thickness, while cervical lymph nodes were assessed in terms of their size, number, and grouping or confluence and associated changes, if any. MRI parameters were analyzed by three expert radiologists who were blinded to clinical findings. Tumor size in all three dimensions [Figure 2] was assessed for its relation with lymph node metastasis. For measuring tumor thickness, a horizontal line joining two tumor–mucosa junctions was drawn as the reference line and tumor thickness was measured by drawing perpendicular lines from the said reference line to the point of maximal tumor projection and invasion as seen on MRI images and calculated as the greatest determined tumor thickness by adding these two parameters [Figure 3]. The diagnosis of lymph node metastasis was made based on specific imaging criteria on MRI including a size >8 mm and round shape. Size criterion was taken as standard and diagnostic reliability of all other variables was calculated in relation to it in prediction of cervical lymph node metastasis [Figure 4]. All patients were assessed for tumor size, lymph node metastasis, lymph nodal grouping [Figure 5], and peri-neural spread of tumor [Figures 6 and 7] using MRI, while diagnostic reliability for lymph node metastasis in relation to tumor thickness was calculated. The results obtained were, then, subjected to statistical analysis, while sensitivity, specificity, positive and negative predictive values, and accuracy were also calculated.

Statistical analysis used

Statistical analysis was done using Statistical Package for the Social Sciences (SPSS) version 17.0 (SPSS Inc., Chicago, IL, USA), while paired *t*-test was performed for evaluating size of tumor and lymph node recorded on clinical and imaging findings. A *P* < 0.05 was considered statistically significant.

Results

The age of the patients in the study ranged from 37 to 84 years, with a mean age of 60 years. The distribution of cases according to age and gender is shown in Table 1

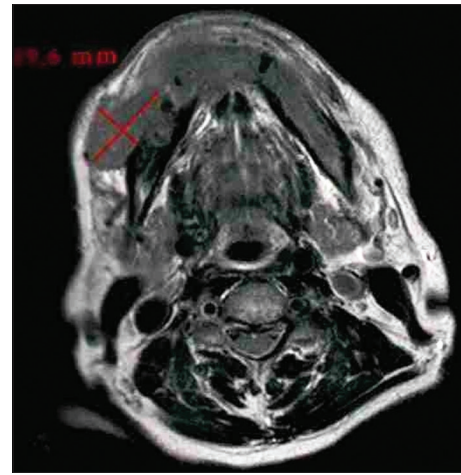


Figure 2: Tumor size on magnetic resonance imaging image (axial view)

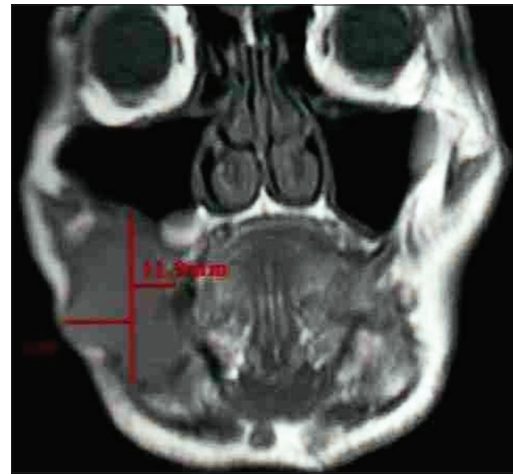


Figure 3: Tumor thickness on magnetic resonance imaging image (coronal view)

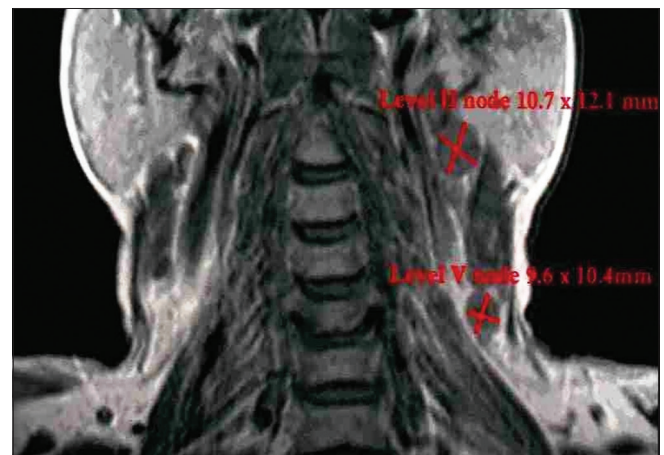


Figure 4: Lymph node size on magnetic resonance imaging image (coronal view)

while by site, tumor differentiation, and FNAC-positive lymph nodes in Table 2. Out of the 24 patients included in study with palpable lymph nodes, 20 lymph nodes were found positive for FNAC confirming metastatic spread [Table 2]. Table 3 reveals the distribution of cases

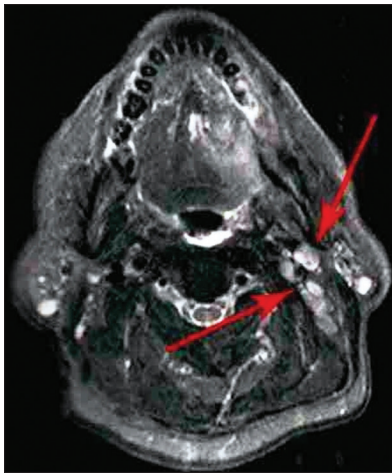


Figure 5: Lymph node grouping on magnetic resonance imaging image (axial view)

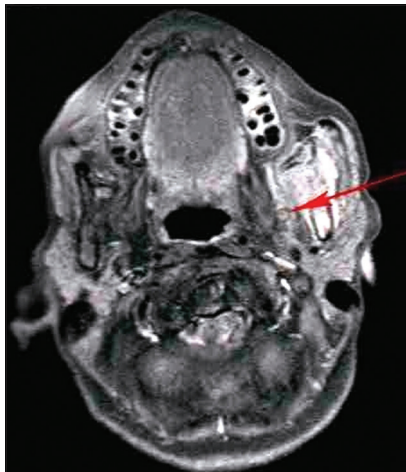


Figure 6: Peri-neural spread on magnetic resonance imaging image (axial view)

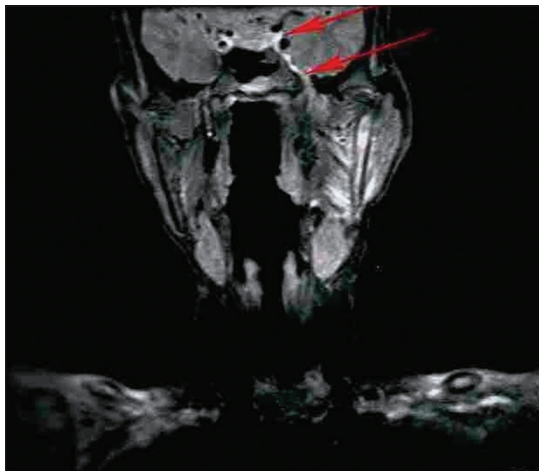


Figure 7: Peri-neural spread on magnetic resonance imaging image (coronal view)

by clinical and imaging staging, wherein it was observed that five cases were upgraded from T2 to T3, two cases from T3 to T4, while only one patient was downgraded from T2 to T1 on MRI examination. On evaluating lymph

Table 1: Distribution of cases by age and gender

Personal characteristics	n (%)
Age (years)	
Up to 50	6 (25.0)
51-65	10 (41.7)
Above 65	8 (33.3)
Sex	
Male	15 (62.5)
Female	9 (37.5)
Total	24 (100.0)

Table 2: Distribution of cases by site, tumor differentiation and fine-needle aspiration cytology-positive lymph nodes

Variable	n (%)
Site	
Alveolus	11 (45.8)
Tongue	6 (25.0)
Buccal mucosa	7 (29.2)
Total	24 (100)
Tumor differentiation	
Poor	2 (8.3)
Moderate	7 (29.2)
Well	15 (62.5)
Total	24 (100.0)
Lymph node status	
Positive	20 (83.33)
Negative	4 (16.67)
Total	24 (100.0)

Table 3: Distribution of cases by clinical and imaging staging

Stage	Clinical, n (%)	Imaging, n (%)
T1N1M0	1 (4.2)	2 (8.3)
T2N0M0	2 (8.3)	1 (4.2)
T2N1M0	14 (58.3)	9 (37.5)
T3N1M0	7 (29.2)	9 (37.5)
T4N1M0	-	3 (12.5)
Total	24 (100.0)	24 (100.0)

nodes, five cases (20.83%) were upgraded from N0 to N1 while one case (4.17%) was upgraded from N2a to N2b as observed on MRI. Table 4 reveals the relationship between tumor thickness and lymph node metastasis for all levels of lymph nodes wherein tumor thickness observed in the present study varied from 1.4 to 5.6 cm, while positive cases for lymph node metastasis were found to be more when tumor thickness was >3 cm in case of both Level I (88.89%) and all levels (81.25%) of lymph nodes, with the corresponding values being statistically significant ($P < 0.05$). Table 5 shows the diagnostic reliability of different cutoff thickness in relation to lymph node metastasis for all levels of lymph nodes, wherein the diagnostic accuracy for the detection of lymph nodal metastasis in relation to tumor thickness of 2 cm, 3 cm, and 4 cm was reported to be 40.0%, 32.0%, and 76.0%, respectively, for Level I and 36.96%, 41.30%,

Table 4: Relationship between tumor thickness and lymph node metastasis for all levels of lymph nodes

Levels	Tumor thickness (cm)	Lymph node metastasis		Total, n (%)	χ^2	P
		Negative	Positive			
Level I	Up to 2	4	2	6 (33.33)	7.6830	0.0210*
	2-3	7	3	10 (30.0)		
	>3	1	8	9 (88.89)		
	Total	12	13	25 (52.0)		
All levels	Up to 2	8	3	11 (27.27)	8.9260	0.0120*
	2-3	11	8	19 (42.11)		
	>3	3	13	16 (81.25)		
	Total	22	24	46 (52.17)		

*P<0.05: Statistically significant

Table 5: Diagnostic reliability of different cut-off thickness in relation to lymph node metastasis for all levels of lymph nodes

Levels	Tumor thickness (cm)	Specificity (%)	Sensitivity (%)	Positive predictive value (%)	Negative predictive value (%)	Accuracy (%)
Level I	2	66.67	15.38	42.11	33.33	40.00
	3	41.67	23.08	33.33	30.00	32.00
	4	91.67	61.54	68.75	88.89	76.00
All levels	2	63.64	12.50	40.00	27.27	36.96
	3	50.00	33.33	40.74	42.11	41.30
	4	86.36	54.17	63.33	81.25	69.57

and 69.57% for all levels of lymph nodes. Table 6 shows the relationship between lymph node number and metastasis, while Table 7 shows the diagnostic reliability for lymph node metastasis in relation to lymph node number, grouping, and associated changes for all levels of lymph nodes. The diagnostic accuracy for lymph node metastasis in relation to lymph node number, grouping, and associated changes was found to be 56.0%, 56.0%, and 52.0%, respectively, for Level I while 60.87%, 58.7%, and 50.0% for all levels of lymph nodes. Table 8 shows comparison of clinical and imaging staging with varied tumor-related parameters and lymph node size (in mm), wherein on analysis, it was found that tumor sizes identified on imaging with a mean of 4.04 mm for length and 3.08 mm for width, respectively, were significantly higher than as assessed by clinical staging with a mean of 2.94 mm and 2.47 mm for length and width, respectively. Similarly, the size of lymph nodes identified on imaging with a mean of 11.45 mm was found to be higher than as assessed by clinical staging with a mean of 8.00 mm, with the corresponding values being statistically significant ($P < 0.05$). Table 9 reveals overall diagnostic reliability of MRI staging for lymph node metastasis, wherein it could be observed that the overall specificity, sensitivity, and positive and negative predictive values as observed on imaging were found to be 100.0%, 75.0%, 72.73%, and 100.0%, respectively, while the overall accuracy achieved was 85.0%.

Discussion

Although CT remains the most widely used imaging modality, it delivers a very high dose of radiation to

Table 6: Relationship between lymph node number and metastasis

Number of lymph nodes enlarged	Lymph node metastasis		Total
	Negative, n (%)	Positive, n (%)	
1	17 (56.67)	13 (43.33)	30
2	4 (36.36)	7 (63.64)	11
3	0 (0.00)	1 (100.00)	1
4	1 (50.00)	1 (50.00)	2
5	0 (0.00)	1 (100.00)	1
6	0 (0.00)	1 (100.00)	1
Total	22 (47.83)	24 (52.17)	46

 $\chi^2=3.0701$, $P=0.2152$

patients, while on the contrary, MRI is a safer and new procedure for the evaluation of OSCCs and associated lymphadenopathy which is preferred for its excellent soft tissue resolution, especially in three-dimensional visualizations.^[21,22] Ultrasonography, though used for soft tissue imaging, is a highly operator-dependent imaging modality.^[16] Although MRI is considered to be a costly imaging modality till date, its use for accurate preoperative evaluation of tumor size and metastatic lymphadenopathy can significantly decrease morbidity in OSCC patients.^[4] The use of MRI, in the head and neck region, is, also, supported by the facts that orofacial tissues have variable amount of fat in different regions and tumor extent can be clearly seen on MRI images by fat-suppression techniques. Moreover, MRI images are free from metal streak artifacts seen on CT images.^[22] The major limitations of MRI, however, include its restricted availability and difficulty in performing MRI scan in claustrophobic, old, and uncooperative patients. MRI is, also, contraindicated in

Table 7: Diagnostic reliability for lymph node metastasis in relation to lymph node number, grouping and associated changes for all levels of lymph nodes

Levels	Lymph node	Specificity (%)	Sensitivity (%)	Positive predictive value (%)	Negative predictive value (%)	Accuracy (%)
Level I	Number	75.00	38.46	52.94	62.50	56.00
	Grouping	83.33	30.77	52.63	66.67	56.00
	Associated changes	100.00	7.69	50.00	100.00	52.00
All levels	Number	77.27	45.83	56.67	68.75	60.87
	Grouping	81.82	37.50	54.55	69.23	58.7
	Associated changes	100.00	4.17	48.89	100.00	50.00

Table 8: Comparison of clinical and imaging staging with varied tumor-related parameters and lymph node size (mm)

Staging	<i>n</i>	Mean	SD	Mean differences	<i>t</i>	<i>P</i>
Tumor length (mm)						
Clinical	24	2.94	1.18	−1.10	−7.22	0.0001*
Imaging	24	4.04	1.71			
Tumor width (mm)						
Clinical	24	2.47	0.97	−0.61	−3.38	0.0001*
Imaging	24	3.08	1.53			
Lymph node size (mm)						
Clinical	20	8.00	5.48	−3.45	4.21	0.0005*
Imaging	20	11.45	7.22			

*P<0.05: Statistically significant. SD: Standard deviation

Table 9: Overall diagnostic reliability of magnetic resonance imaging staging for lymph node metastasis

Clinical staging	Imaging staging		Cut-off
	Negative	Positive	
Negative	8	3	11
Positive	0	9	9
Total (metastasis)	8	12	20
Specificity (%)		100.00	
Sensitivity (%)		75.00	
Positive predictive value (%)		72.73	
Negative predictive value (%)		100.00	
Accuracy (%)		85.00	

patients with ferromagnetic-based implants, including cardiac pacemakers and aneurysmal bone and vascular clips.^[23-25]

Inaccuracies in clinical examination have been well documented. In the present study, tumor size as evaluated by TNM staging based on MRI was found to be higher for most of the cases as compared to that documented on clinical examination. Only one case was downgraded from T2 to T1 on MRI examination, the probable reason for which could be that the largest tumor dimension got obscured within 4–7 mm slice thickness used for acquisition of MRI images. Furthermore, nodal involvement was found to be more when evaluated with MRI as compared to clinical staging, wherein 5 cases (20.83%) were upgraded from N0 to N1 while

one case (4.17%) was upgraded from N2a to N2b as observed on MRI. It was, also, evident from findings of the present study that whenever tumor sizes were larger, widespread nodal metastases were noticed while a significant difference was noted in tumor sizes as identified on imaging than as assessed by clinical staging. Similarly, sizes of lymph nodes identified on imaging were found to be higher than as assessed by clinical staging, with the corresponding values being statistically significant ($P < 0.05$). The results of the present study revealed the overall specificity, sensitivity, and positive and negative predictive values as observed on imaging to be 100.0%, 75.0%, 72.73%, and 100.0%, respectively, while the overall accuracy achieved was 85.0%.

Bipat *et al.*,^[26] after reviewing 57 high-quality studies, concluded that sensitivity of MRI was higher (60%) as compared to CT (43%) for detecting metastatic lymph nodal involvements. Hayashi *et al.*,^[27] however, reported an accuracy of 75% with a cutoff value of 5 mm tumor thickness for subsequent lymph node metastasis when using CT. In the present study, a diagnostic accuracy of 76.0% was achieved with a cutoff value of 4 cm tumor thickness for Level I while 69.57% for all levels of lymph nodes when using MRI. Diagnostic accuracy reported by Hayashi *et al.*^[27] using CT and the present study using MRI is comparable; however, disadvantages of CT have to be noted. Significantly increased risk for cervical lymph nodal metastasis was, also, noticed by Fukano *et al.*^[15] and O-Charoenrat *et al.*^[16] with tumor thickness of >5 mm for oral and oropharyngeal carcinomas. Furthermore, it is true that tumor deposits within a node are only microscopic and detection of metastasis is usually difficult at microscopic level; however, when metastases are large enough to be detected by CT or MRI, criteria are necessary to stage the disease.^[25]

There are no clear recommendations regarding size criterion and different values have also been studied.^[28] The present study used a size criterion of 8 mm as standard for predicting lymph node metastasis in analyzing accuracy of other imaging criteria. There are very few studies that have considered number of lymph nodes involved as an imaging criterion to predict prognosis in OSCCs, though literature review reveals worse prognosis

whenever more number of lymph nodes were involved in given carcinoma.^[29] In the present study, diagnostic accuracy for lymph node metastasis in relation to lymph node number, grouping, and associated changes was found to be 56.0%, 56.0%, and 52.0%, respectively, for Level I while 60.87%, 58.7%, and 50.0% for all levels of lymph nodes. Furthermore, specificity values of 83.33% and 81.82% were observed in the present study in relation to grouping of lymph nodes as a diagnostic criterion for predicting lymph nodal metastasis; the finding, however, was contradictory to the finding of the study conducted by van den Brekel *et al.*,^[28] who stated that grouping criterion did not increase specificity for the detection of lymph node metastasis. Furthermore, in the present study, a sensitivity of 4.17%–7.69% while a specificity of 100.0% for peri-neural spread as imaging criterion were reported on MRI, though relatively higher values of sensitivity and specificity were observed in the study conducted by Hanna *et al.*,^[30] with a reported sensitivity of 100% and specificity of 85% using MRI and 88% and 89%, respectively, using CT. The low value of sensitivity observed in the present study, however, can be attributed to the fact that only one case in the present study was found to have associated changes with lymph node metastasis in the form of peri-neural spread on MRI.

Clinical examination remains the worldwide standard and the very first step for initial screening and evaluation of OSCCs; however, it fails to define exact tumor size and extent and associated lymph nodal metastasis. Furthermore, surface size is the main verifiable clinical parameter available before treatment because nodal spread estimates are often erroneous while biopsies, also, often do not reflect the whole tumor histology.^[31] Furthermore, thickness of tumor, or its volume, even if, assessed before treatment, can only be a rough estimate which are not mentioned in the official TNM manual.^[32,33] In patients with head and neck carcinomas, prognosis is usually obtained based on TNM classification which is based on the clinical criteria and is highly useful, especially to assess the essential features such as local extension, regional dissemination, and distant metastasis.^[34,35] However, this classification lacks a clear idea about aggressiveness of tumor and inflammatory versus metastatic lymph nodal enlargements. Clinical impression of nodal metastasis on the first examination is often overestimated, and this might be because of the regional inflammatory reaction to a metastatic node. In addition, histopathological examination, which is the gold standard, is currently being done postoperatively only. In such circumstances, a study correlating MRI findings and histologic tumor thickness and associated lymph nodal metastasis in the assessment of OSCCs gives a clear view about this aspect. One such study done by Lam *et al.*^[17] in oral tongue carcinomas stated that radiologic tumor thickness as measured

on contrast-enhanced MRI images had a significant correlation with histologic tumor thickness.

OSCCs may have different behaviors in different areas of the oral mucosa. Thus, traditional TNM clinical staging fails to predict exact prognosis. It has, also, been reported previously that when dealing with primary tumors, advanced cases with infiltration of adjacent structures were hardly assessed on clinical examination with the percentage of accuracy found to be higher when CT and MRI were used for classification and staging of tumor as compared to TNM clinical staging alone.^[36] In the present study, only 40% of cases were found to be true positive for detecting lymph nodal metastasis using clinical diagnostic criteria, while the numbers were 55% using imaging criteria. Thus, imaging criteria were found to be more accurate than clinical diagnostic criteria. This might, also, be because none of the available imaging criteria for lymph nodal metastasis are standardized till date.

It is of further interest to note that few cases in the present study, particularly tongue and buccal mucosa, showed involvement of Level III and IV lymph nodes on MRI but were clinically occult (N0), thereby emphasizing the significance of MRI in providing useful information regarding treatment planning in such cases. By detecting some otherwise clinically occult lymphadenopathy, MRI may have increased sensitivity for detecting positive nodes and consequently may decrease risk of occult metastasis which might be of extreme significance in decision-making as treatment strategies for N0 and N1 or N2 necks differ distinctly.^[37] The comparatively lower sensitivity and specificity reported in the present study might be attributed to the reason that cases involving three different regions of the oral cavity were included which might have different patterns of nodal metastasis. Furthermore, OSCCs involving alveolus do not spread to lymph nodes as rapidly as the ones involving tongue and buccal mucosa.^[4,5,16,27]

Conclusions

The present study revealed that clinical diagnostic criteria alone were not sufficient and reliable for detecting metastatic lymphadenopathy, highlighting the significance of advanced imaging modalities such as MRI for an efficient preoperative diagnostic workup as well as a tool for planning treatment in patients with practically incurable OSCCs. Based on the findings of present study, it was, also, observed that whenever tumor size, particularly, tumor thickness of >4 cm, was observed, cervical lymph nodal metastasis could be predicted accurately which, in turn, had a significant impact on prognosis. The study did encounter a limitation in the form of enhancement of inflamed and edematous soft

tissues on MRI, especially on T2-weighted, spin-echo images, but this was seen as a common drawback in previous studies as well, related to MRI.

Future research directions

Although MRI is an extremely useful advanced imaging modality for an efficient preoperative diagnostic workup and as a tool for planning treatment, it might not provide equally useful information postsurgery and/or radiotherapy when anatomical planes are distorted. In such cases, fluorodeoxyglucose-based positron emission tomography may be used to get necessary information regarding residual/recurrent malignant and metastatic foci and associated lymphadenopathy.^[20] Furthermore, in the future, newer technologies applied to MRI including MRI microimaging and functional MRI might give more advanced outcomes with higher diagnostic and predictive accuracies and help in improving survival of affected patients.^[38]

Acknowledgment

We would acknowledge all the patients who contributed in the study, without whom, this study would not have been feasible.

Financial support and sponsorship

Nil.

Conflicts of interest

There are no conflicts of interest.

References

- Johnson N. Global epidemiology. In: Shah JP, Johnson NW, Batsakis JG, editors. *Oral Cancer*. London: Martin Dunitz Publication; 2003.
- Divya MR, Nagesh KS, Iyengar AR, Gupta J, Reddi NS. Recent advances in the treatment of oral cancer: An overview. *J Indian Acad Oral Med Radiol* 2006;18:98-102.
- Batsakis JG. Squamous cell carcinoma of the oral cavity and the oropharynx. In: *Tumors of the Head and Neck: Clinical and Pathological Considerations*. 2nd ed. Baltimore: Williams and Wilkins; 1979.
- Greenberg MS, Glick M, Ship JA. *Burket's Oral Medicine, Diagnosis and Treatment*. 10th ed. Ontario: BC Decker, Hamilton; 2003.
- Shafer WG, Levy BM, Hine MG. *A Textbook of Oral Pathology*. 4th ed. Philadelphia: WB Saunders Co.; 1983.
- Chong V. Cervical lymphadenopathy: What radiologists need to know. *Cancer Imaging* 2004;4:116-20.
- Friedman M, Roberts N, Kirshenbaum GL, Colombo J. Nodal size of metastatic squamous cell carcinoma of the neck. *Laryngoscope* 1993;103:854-6.
- Hillsamer PJ, Schuller DE, McGhee RB Jr., Chakeres D, Young DC. Improving diagnostic accuracy of cervical metastases with computed tomography and magnetic resonance imaging. *Arch Otolaryngol Head Neck Surg* 1990;116:1297-301.
- McGuirt WF, Williams DW 3rd, Keyes JW Jr., Greven KM, Watson NE Jr., Geisinger KR, *et al.* A comparative diagnostic study of head and neck nodal metastases using positron emission tomography. *Laryngoscope* 1995;105:373-5.
- Takashima S, Sone S, Nomura N, Tomiyama N, Kobayashi T, Nakamura H, *et al.* Non-palpable lymph nodes of the neck: Assessment with US and US-guided fine-needle aspiration biopsy. *J Clin Ultrasound* 1997;25:283-92.
- Yucel T, Saatci I, Sennaroglu L, Cekirge S, Aydingoz U, Kaya S. MR imaging in squamous cell carcinoma of the head and neck with no palpable lymph nodes. *Acta Radiol* 1997;38:810-4.
- Goto M, Hasegawa Y, Terada A, Hyodo I, Hanai N, Ijichi K, *et al.* Prognostic significance of late cervical metastasis and distant failure in patients with Stage I and II oral tongue cancers. *Oral Oncol* 2005;41:62-9.
- Som PM, Curtin HD, Mancuso AA. An imaging-based classification for the cervical nodes designed as an adjunct to recent clinically based nodal classifications. *Arch Otolaryngol Head Neck Surg* 1999;125:388-96.
- Subramanian S, Sankaranarayanan R, Bapat B, Somanathan T, Thomas G, Mathew B, *et al.* Cost-effectiveness of oral cancer screening: Results from a cluster randomized controlled trial in India. *Bull World Health Organ* 2009;87:200-6.
- Fukano H, Matsuura H, Hasegawa Y, Nakamura S. Depth of invasion as a predictive factor for cervical lymph node metastasis in tongue carcinoma. *Head Neck* 1997;19:205-10.
- O-charoenrat P, Pillai G, Patel S, Fisher C, Archer D, Eccles S, *et al.* Tumour thickness predicts cervical nodal metastases and survival in early oral tongue cancer. *Oral Oncol* 2003;39:386-90.
- Lam P, Au-Yeung KM, Cheng PW, Wei WI, Yuen AP, Trendell-Smith N, *et al.* Correlating MRI and histologic tumor thickness in the assessment of oral tongue cancer. *AJR Am J Roentgenol* 2004;182:803-8.
- Po Wing Yuen A, Lam KY, Lam LK, Ho CM, Wong A, Chow TL, *et al.* Prognostic factors of clinically Stage I and II oral tongue carcinoma – A comparative study of stage, thickness, shape, growth pattern, invasive front malignancy grading, Martinez-Gimeno score, and pathologic features. *Head Neck* 2002;24:513-20.
- Yuen AP, Lam KY, Wei WI, Lam KY, Ho CM, Chow TL, *et al.* A comparison of the prognostic significance of tumor diameter, length, width, thickness, area, volume and clinico-pathological features of oral tongue carcinoma. *Am J Surg* 2000;180:139-43.
- Rumboldt Z, Day TA, Michel M. Imaging of oral cavity cancer. *Oral Oncol* 2006;42:854-65.
- White SC, Pharoah MJ. *Oral Radiology, Principles and Interpretation*. 5th ed. St. Louis, Missouri: Mosby; 2004.
- Connor SE, Olliff JF. Imaging of malignant cervical lymphadenopathy. *Dentomaxillofac Radiol* 2000;29:133-43.
- Sumi M, Sakihama N, Sumi T, Morikawa M, Uetani M, Kabasawa H, *et al.* Discrimination of metastatic cervical lymph nodes with diffusion-weighted MR imaging in patients with head and neck cancer. *AJNR Am J Neuroradiol* 2003;24:1627-34.
- Fischbein NJ, Noworolski SM, Henry RG, Kaplan MJ, Dillon WP, Nelson SJ. Assessment of metastatic cervical adenopathy using dynamic contrast-enhanced MR imaging. *AJNR Am J Neuroradiol* 2003;24:301-11.
- Som PM. Detection of metastasis in cervical lymph nodes: CT and MR criteria and differential diagnosis. *AJR Am J Roentgenol* 1992;158:961-9.
- Bipat S, Glas AS, van der Velden J, Zwinderman AH, Bossuyt PM, Stoker J. Computed tomography and magnetic resonance imaging in staging of uterine cervical carcinoma: A systematic review. *Gynecol Oncol* 2003;91:59-66.
- Hayashi T, Ito J, Taira S, Katsura K. The relationship of primary tumor thickness in carcinoma of the tongue to subsequent lymph node metastasis. *Dentomaxillofac Radiol* 2001;30:242-5.
- van den Brekel MW, Stel HV, Castelijns JA, Nauta JJ, van der Waal I, Valk J, *et al.* Cervical lymph node metastasis: Assessment of radiologic criteria. *Radiology* 1990;177:379-84.
- Shingaki S, Takada M, Sasai K, Bibi R, Kobayashi T, Nomura T,

- et al.* Impact of lymph node metastasis on the pattern of failure and survival in oral carcinomas. *Am J Surg* 2003;185:278-84.
30. Hanna E, Vural E, Prokopakis E, Carrau R, Snyderman C, Weissman J, *et al.* The sensitivity and specificity of high-resolution imaging in evaluating peri-neural spread of adenoid cystic carcinoma to the skull base. *Arch Otolaryngol Head Neck Surg* 2007;133:541-5.
31. van den Brekel MW, van der Waal I, Meijer CJ, Freeman JL, Castelijns JA, Snow GB, *et al.* The incidence of micro-metastases in neck dissection specimens obtained from elective neck dissections. *Laryngoscope* 1996;106:987-91.
32. Fleming ID, Cooper JS, Henson DE, Hutter RV, Kennedy BJ, American Joint Committee on Cancer, editors. *Cancer Staging Manual*. 5th ed. Philadelphia, PA: Lippincott-Raven; 1997.
33. Sobin LH, Wittekind CH, International Union against Cancer UICC, editors. *TNM Classification of Malignant Tumour*. 5th ed. Baltimore, MD: Wiley-Liss; 1997.
34. Choi KK, Kim MJ, Yun PY, Lee JH, Moon HS, Lee TR, *et al.* Independent prognostic factors of 861 cases of oral squamous cell carcinoma in Korean adults. *Oral Oncol* 2006;42:208-17.
35. Costa Ade L, Pereira JC, Nunes AA, Arruda Mde L. Correlation between TNM classification, histological grading and anatomical location in oral squamous cell carcinoma. *Pesqui Odontol Bras* 2002;16:216-20.
36. Bryne M, Nielsen K, Koppang HS, Dabelsteen E. Reproducibility of two malignancy grading systems with reportedly prognostic value for oral cancer patients. *J Oral Pathol Med* 1991;20:369-72.
37. Castelijns JA, van den Brekel MW. Detection of lymph node metastases in the neck: Radiologic criteria. *AJNR Am J Neuroradiol* 2001;22:3-4.
38. Kuriakose MA, Loree TR, Hicks WL, Welch JJ, Wang H, DeLacure MD. Tumour volume estimated by computed tomography as a predictive factor in carcinoma of the tongue. *Br J Oral Maxillofac Surg* 2000;38:460-5.