

## Review Article

# Advances in bronchoscopy for lung cancer

Samjot Singh Dhillon<sup>1,2,\*</sup>, Elisabeth U. Dexter<sup>3,4</sup>

Departments of <sup>1</sup>Medicine-Pulmonary Medicine and Thoracic Oncology, Roswell Park Cancer Institute, and <sup>2</sup>Medicine, State University of New York at Buffalo, <sup>3</sup>Thoracic Surgery, Roswell Park Cancer Institute, and <sup>4</sup>Surgery, State University of New York at Buffalo, New York, USA

E-mail: Samjot.Dhillon@Roswellpark.org

\*Corresponding author

Published: 31 December, 2012

Journal of Carcinogenesis 2012, 11:19

This article is available from: <http://www.carcinogenesis.com/content/11/1/19>

© 2012 Dhillon

Received: 15 July, 2012

Accepted: 13 December, 2012

## Abstract

Bronchoscopic techniques have seen significant advances in the last decade. The development and refinement of different types of endobronchial ultrasound and navigation systems have led to improved diagnostic yield and lung cancer staging capabilities. The complication rate of these minimally invasive procedures is extremely low as compared to traditional transthoracic needle biopsy and surgical sampling. These advances augment the safe array of methods utilized in the work up and management algorithms of lung cancer.

**Keywords:** Bronchoscopy, electromagnetic navigation, endobronchial ultrasound, lung nodule

## INTRODUCTION

The recent advances in bronchoscopic procedures coupled with the progress in the treatment of lung cancer have brought bronchoscopists to the forefront in the management of lung cancer. The requirement of enough tissue for accurate diagnosis, differentiation of squamous from non-squamous histology, and mutation testing, along with the need for accurate staging has become critical in the treatment of lung cancer.<sup>[1,2]</sup> The traditional role of bronchoscopy in lung cancer has been to obtain a diagnosis and provide palliative care with debulking modalities and stenting. Transbronchial needle aspiration (TBNA) of mediastinal lymph nodes or masses is helpful for diagnosing and staging lung cancer, but the yield is variable and this technique is underutilized.<sup>[3,4]</sup> Transbronchial biopsy with fluoroscopy is used for diagnosis of parenchymal lung lesions but even in the best of hands, the

yield is less than optimal, especially for peripheral and smaller lesions.<sup>[5,6]</sup> The advent of endobronchial ultrasound (EBUS) and electromagnetic navigation bronchoscopy (ENB) has enhanced our diagnostic yield, leading to superior staging capabilities and improved patient management. These two technological advances will be the focus of this mini-review.

## ENDOBONCHIAL ULTRASOUND

The inability of the standard bronchoscope to visualize beyond the main airway and into the peripheral smaller airways is overcome by EBUS, which is heralded as the most significant advance in the field of bronchoscopy in the last decade. Three types of EBUS probes are available: (1) Radial balloon (RB-EBUS) (2) Ultra-miniature radial (UM-EBUS), and (3) Convex or curvilinear (CP-EBUS).<sup>[7,8]</sup>

### Radial probe endobronchial ultrasound (Balloon probe and ultra-miniature probe)

The radial probe EBUS is inserted through the working channel of a bronchoscope. It has a 20-MHz transducer at its tip that rotates 360° perpendicular to the insertion and obtains detailed images of the airway wall and surrounding structures. The balloon of the balloon probe EBUS is filled with normal saline to facilitate close contact with airway wall.

#### Access this article online

##### Quick Response Code:



##### Website:

[www.carcinogenesis.com](http://www.carcinogenesis.com)

##### DOI:

10.4103/1477-3163.105337

It was initially used to guide the localization and TBNA of mediastinal and hilar lymph nodes, but the probe had to be removed for allowing insertion of the TBNA needle through the working channel of the bronchoscope. This use has generally been replaced by the curvilinear EBUS, which allows real-time TBNA. Visualization of five to seven layers of the tracheal and proximal bronchial airway wall with RB-EBUS has been described. Several studies have demonstrated its usefulness in assessing the depth of malignant tracheobronchial wall invasion and to direct management decisions about photodynamic therapy for carcinoma *in situ*.<sup>[9-11]</sup>

The UM-EBUS probe with or without guide sheath is used to identify and sample peripheral lesions [Figure 1]. It has been shown to be superior to the traditional transbronchial biopsy for lesions < 3 cm and for lesions not visible by fluoroscopy.<sup>[12,13]</sup> In a randomized trial comparing UM-EBUS with traditional transbronchial biopsy, yield was not significantly different for lesions > 3 cm. However, the sensitivity of UM-EBUS for lesions < 3 cm was 75% and for lesions < 2 cm was 71% as compared to traditional transbronchial biopsy, where sensitivity was only 31% and 23%, respectively.<sup>[12]</sup> The yield is much higher when the UM-EBUS probe is within the lesion instead of simply adjacent to the lesion.<sup>[14,15]</sup> UM-EBUS, used concomitantly with electromagnetic navigation (EMN) bronchoscopy, has been shown to improve the diagnostic yield to 88%, which was significantly more than either procedure alone ( $P$  0.02).<sup>[16]</sup>

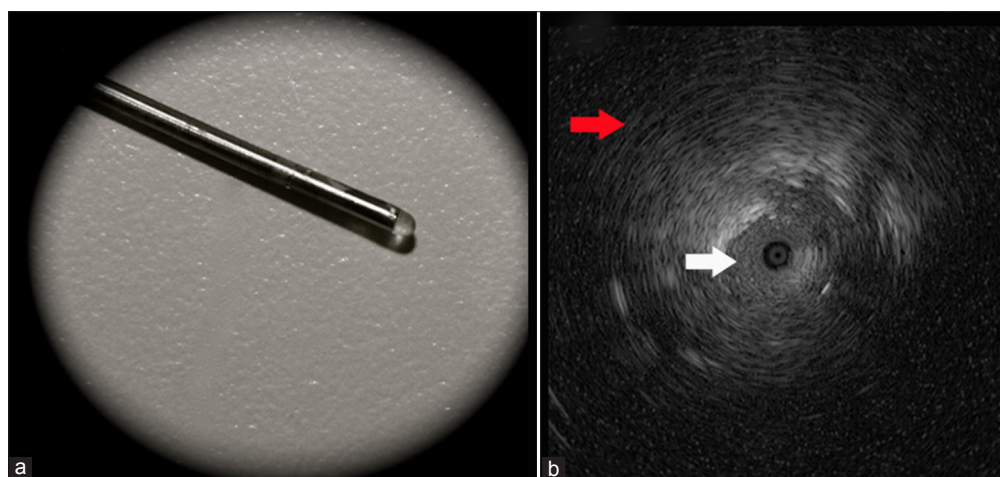
### Convex probe or curvilinear endobronchial ultrasound

The CP-EBUS has a convex probe transducer with a frequency of 7.5 MHz (new CP-EBUS also have 5, 10, and

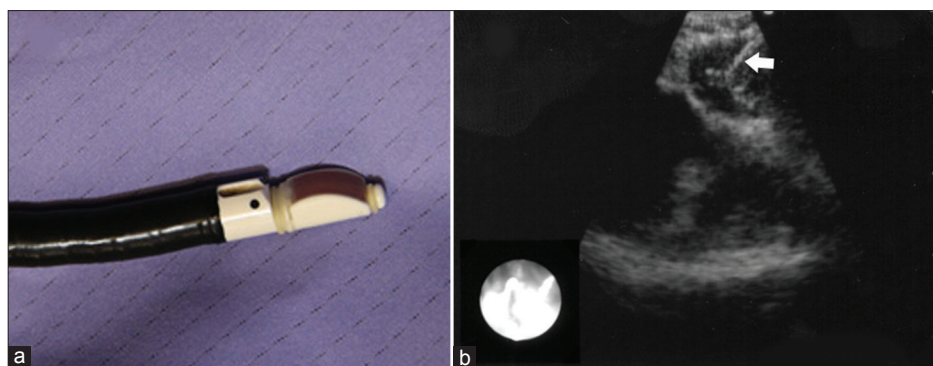
12 MHz capability; higher frequency means better resolution but less depth) with an 80° field of view and 35° forward view [Figure 2a and b]. It is bigger than a regular flexible fiberoptic bronchoscope with distal end outer diameter of 6.9 mm, insertion tube outer diameter of 6.2 mm, and working channel of 2.2 mm (Olympus BF-UC180F). Due to the larger size of the bronchoscope, the oral insertion is used under either conscious sedation or general anesthesia. Utilizing the water filled balloon at the tip to obtain better contact with the airway wall optimizes the ultrasound image. Doppler can be used to identify blood vessels and vascularity of lymph nodes. A 21- or 22-G needle protrudes 2-4 cm to sample lymph node under real-time ultrasound guidance. The CP-EBUS can assess lung masses close to airway and several lymph node stations including upper and lower paratracheal (stations 2 and 4), retrotracheal (3P), subcarinal (7), hilar/lobar (10 and 11), and at times interlobar (12) stations. Due to the larger size of scope, it usually cannot pass beyond the central airways into distal segmental stations. Nodes as small as 5 mm can be aspirated.<sup>[17,18]</sup> At least; three passes from each lymph node station are needed for optimal yield.<sup>[19]</sup>

## ENDOBONCHIAL ULTRASOUND FOR MEDIASTINAL STAGING OF LUNG CANCER

Mediastinal staging is the most important step in initial patient evaluation after excluding distant metastasis.<sup>[2]</sup> Literature of last few years has been replete with several studies of CP-EBUS in staging of lung cancer. A pooled analysis of 12 studies of EBUS with 1292 patients (103 of them had radial ultrasound) showed a sensitivity of 93% (79-99%), specificity of 100%, and false-negative rate of 9% (1-37%) for mediastinal staging when the mean prevalence of mediastinal metastasis



**Figure 1: (a) An ultra-miniature radial-endobronchial ultrasound (UM-EBUS) endobronchial ultrasound probe, which can be passed through the working channel of a bronchoscope. (b) Ultrasound view of the peripheral lesion with UM-EBUS. The small circular area in the center is the probe inside the lesion. The white arrow shows the lesion and the red arrow indicates the surrounding normal lung, which has the typical snowstorm appearance**



**Figure 2: (a) The Convex probe or curvilinear-endobronchial ultrasound with an inflatable balloon on the ultrasound transducer. (b) The EBUS view of small < 1 cm paratracheal lymph node with needle (white arrow) seen inside the node**

was 63%.<sup>[8]</sup> CP-EBUS has been shown to be more accurate than computed tomography (CT) and positron emission tomography (PET) for the staging of lung cancer.<sup>[20]</sup> Cervical mediastinoscopy is currently considered the “Gold Standard” of mediastinal staging but can only access stations 2, 3A, 4, and 7. The average sensitivity of mediastinoscopy is 80% and the average false-negative rate is 10%.<sup>[21]</sup> A significant proportion of false-negative cases are likely due to nodes not accessible by mediastinoscopy which is also operator dependent.<sup>[21]</sup> Mediastinoscopy is more expensive and resource intensive than EBUS, requires general anesthesia, and leaves a scar although the former two statements are subject of debate.<sup>[22]</sup> Complications include vascular injury, bleeding, and recurrent laryngeal or phrenic nerve injury. Injury to the esophagus or trachea rarely occurs, but can have chronic and/or devastating effects.<sup>[21,23]</sup> The procedure can be challenging in patients with tracheostomy, unstable cervical spine, and limited neck mobility or in patients with mediastinal scarring caused by factors such as radiation or previous mediastinoscopy. A large patient care survey of 729 hospitals showed that mediastinoscopy is performed infrequently in the management of non-small-cell lung cancer (NSCLC) patients and that lymph node sampling occurred in < 50% of cases suggesting that wide variations exist in the practice and utilization of this technique.<sup>[24]</sup> CP-EBUS is minimally invasive with high sensitivity and is relatively less expensive,<sup>[25]</sup> with very few reported complications. It is a viable option in situations where mediastinoscopy is challenging. However, unlike mediastinoscopy, it may not be able to detect extra-capsular spread of tumor or micrometastasis. The general recommendation is to confirm negative EBUS cases with mediastinoscopy when the clinical situation warrants this.<sup>[22,21]</sup> Similar to mediastinoscopy, EBUS is operator dependent, has a learning curve, and additionally is still not widely available likely due to the acquisition of training and equipment that is necessary. Accurate, reliable, and timely cytology support is paramount for a successful EBUS program.

Few studies have directly compared EBUS with mediastinoscopy. A prospective cross-over trial of 66 patients showed significantly higher diagnostic yield of EBUS as compared to mediastinoscopy (91% vs. 78%,  $P = 0.007$ ) in a population with high N2 disease prevalence of 89%. However, this difference was due to lower yield of mediastinoscopy at the posterior subcarinal station due to difficulty in accessing.<sup>[26]</sup> Also no difference was noted in the determination of overall true pathological “N” stage. A recent prospective trial of 153 patients with confirmed or suspected NSCLC who needed mediastinoscopy for evaluation of surgical resection candidacy was performed. CP-EBUS was found to be comparable to mediastinoscopy in determining the true pathological “N” stage with a prevalence of mediastinal metastasis in this study of 35%.<sup>[18]</sup> While pending further trials, mediastinoscopy will remain the gold standard due to wider availability and the ability to provide larger pathology specimens. EBUS will also take an important place in the mediastinal staging paradigm of lung cancer and may become the first initial mini-invasive procedure of choice. Local expertise, availability of EBUS along with the lymph node size/location, availability of cytology expertise, and overall clinical situation will likely determine the procedure of choice at each facility.

### Complications

The incidence of bleeding and pneumothorax using radial EBUS is low and comparable to that of routine bronchoscopy with transbronchial biopsies.<sup>[13]</sup> Very few complications have been reported with CP-EBUS including hematoma and mediastinal infections.<sup>[27-31]</sup> A case of death was reported in a recent multi-center trial attributed to group A *Streptococcus* bacteremia after an EBUS in a 48-year-old man with Stage IV adenocarcinoma.<sup>[32]</sup> The incidence of bacteremia during EBUS has been reported to be 7% but this incidence is similar to that of flexible bronchoscopy, endoscopic ultrasound (EUS), and gastroscopy.<sup>[33]</sup> Some CP-EBUS needles were reported to release metal particles but the clinical significance of this is not clear.<sup>[34]</sup>

## Special situations

### *Radiologically normal mediastinum*

CP-EBUS has shown to be efficacious for lymph node aspiration in patients with a radiologically normal mediastinum. In a cohort of 97 patients with lung cancer who had normal mediastinal lymph nodes by CT and PET criteria, CP-EBUS was used to aspirate 156 lymph nodes ranging from 5 mm to 10 mm followed by surgical staging. CP-EBUS was able to appropriately detect malignancy in 8 out of 9 patients with surgically confirmed metastatic disease.<sup>[17]</sup>

### *Restaging after neoadjuvant treatment*

EBUS is also a reasonably safe and minimally invasive option for the restaging of the mediastinum after neoadjuvant chemotherapy. However, the negative predictive value in one study was only 20% and negative cases should be confirmed by surgical staging.<sup>[35]</sup>

### *Medical mediastinoscopy: Combining endobronchial ultrasound with endoscopic ultrasound*

EUS is performed through the esophagus and can sample para-esophageal (station 8), pulmonary ligament (station 9), retroperitoneal, celiac lymph nodes, and lesions in the left lobe of liver and left adrenal gland. Combining EUS with EBUS has been shown to have better diagnostic yield for lung cancer than either procedure alone.<sup>[36]</sup> Medical mediastinoscopy (EBUS + EUS) attempted prior to surgical staging can prevent unnecessary thoracotomies.<sup>[37]</sup> Some authors have even reported improved sensitivity of EBUS by introducing it through the esophagus for additional sampling after routine EBUS.<sup>[38]</sup>

### *Non-small-cell lung cancer subtyping and mutation testing*

Several reports have indicated that appropriate cell typing of NSCLC and mutation testing can be successfully done on tissue obtained by EBUS.<sup>[39-41]</sup> A recent large multi-center trial from United Kingdom of 774 patients with suspected lung cancer showed accurate subtyping of NSCLC in 77% of the patients. Only 23% in the study were classified as NSCLC-NOS.<sup>[32]</sup> Addition of immunohistochemistry was helpful in improving subtyping. Furthermore, Epidermal Growth Factor Receptor (EGFR) mutation status could be determined in 90% of the 119 patients on whom it was requested.

### *Evaluation of vasculature*

The latest or 7<sup>th</sup> edition of "TNM" staging by the International Association for the Staging of Lung Cancer (IASLC) clearly delineates vascular and airway landmarks for identifying lymph node stations,<sup>[42]</sup> allowing bronchoscopists to accurately stage the patients. The Doppler feature of EBUS

allows easy identification of vessels. EBUS can aid in the work up of PET-positive areas in the mediastinum and can identify pulmonary embolism and tumor thromboembolism.<sup>[43,44]</sup>

## ELECTROMAGNETIC NAVIGATION BRONCHOSCOPY

As mentioned above, bronchoscopy utilizing fluoroscopy and CT-guided transthoracic biopsy or needle aspiration (TTNA) have been the traditional methods utilized for diagnosis of lung cancer presenting as lung nodules or masses. The reported yield of bronchoscopy for peripheral < 2 cm lesions is low at 34%<sup>[6]</sup> though some studies report the yield as low as 14%.<sup>[5]</sup> This is likely due to difficulty in localizing the lesions with standard endobronchial biopsy tools. Improved yield has been reported when an airway leads directly into the lesions also known as CT-bronchus sign.<sup>[6]</sup> CT-guided TTNA has a very high yield of around 90%,<sup>[6]</sup> but is associated with significant complications with a pneumothorax rate ranging from 15% to 28%.<sup>[45-47]</sup> A recent large US study of 15,865 patients from 4 states reported a post-CT biopsy pneumothorax rate of 15% with 6.6% of these patients required a chest tube. Almost 18% of the 163 patients who experienced hemorrhage required blood transfusion. The patients who had any complication from CT-guided biopsy including hemorrhage or pneumothoraxes had much longer hospital stays and were more likely to develop respiratory failure requiring mechanical ventilation.<sup>[47]</sup> In addition, some lesions are not accessible or are too high risk to CT-guided sampling due to location or presence of underlying lung disease. Examples of anatomic positions that may increase the risk or technically preclude percutaneous biopsy include:<sup>[48,49]</sup>

- a. Proximity to the heart or large vessels.
- b. Proximity to bullous emphysema.
- c. Deep lesions with increased lung parenchyma between the chest wall and the lesion.
- d. Lower lobe lesions near the diaphragm that move significantly with respiration.
- e. Lesions situated such that a fissure must be crossed to obtain a biopsy.

Since the rate of complications with bronchoscopy is low, the last decade has seen a significant push towards method to improve the diagnostic yield of bronchoscopic techniques for pulmonary nodules. In addition to EBUS, various techniques such as virtual bronchoscopy, ENB, and ultrathin bronchoscopes have been developed. A recent meta-analysis reports a pooled diagnostic yield of these techniques at 70%.<sup>[50]</sup> This is much better than traditional bronchoscopy and will hopefully increase further as these techniques are refined and bronchoscopists become more experienced. The complication rate is similar to conventional bronchoscopy



and is extremely low with a pneumothorax rate of 1.6% with 0.7% requiring chest tube and a respiratory failure rate of 0.1%.<sup>[50]</sup> No episode of significant bleeding or death has been reported.<sup>[50]</sup>

The RP-EBUS has already been discussed above. The navigation systems allow better localization of lung lesions and mediastinal/hilar lymph nodes by delineating endobronchial routes to the desired area for biopsy. The technique utilizes a thin-section digital imaging and communications in medicine (DICOM) CT to create a virtual bronchoscopy and bronchial tree. The virtual bronchoscopy is used to route an endobronchial pathway to the lesion prior to the procedure. Several navigation systems are available but most of the published evidence is based on superDimension system (superDimension, Inc. Minneapolis, USA), which is an EMN system, approved by FDA for guiding tools for lung and lymph node biopsy or marker placement.

The superDimension system comprises of four essential components:

1. The I-Logic™ computer software translates DICOM images into a three-dimensional reconstruction of airways and virtual bronchoscopy. It also synchronizes the patient's anatomy with the virtual bronchoscopy by correlating set anatomical endobronchial landmarks. It also automatically generates an endobronchial pathway to the lesions marked for biopsy by the bronchoscopist.
2. A board to create an electromagnetic field surrounding the patient's chest and topical sensors to allow synchronization of the virtual bronchoscopy with the patient's anatomy and with movements such as breathing during the procedure.
3. A steerable handmade and attuned electromagnetic probe called locatable guide (LG).
4. A catheter called the extended working channel (EWC) through which the LG, which is sensed by the electromagnetic field, is passed. This catheter will stay in place after the navigation to the target is achieved and LG is removed to allow passage of biopsy tools to the target.

Prior to the procedure, the bronchoscopist views the CT scan in the axial, sagittal, and coronal planes and marks the areas to be biopsied. The CT images need to be recent and of narrow slice thickness and close intervals to facilitate accurate construction of a virtual bronchoscopic tree by the proprietary software. The software will then generate an endobronchial route to the lesion or, if the bronchoscopist wishes, he/she can manually mark a route. This plan is then saved and transferred to the computer tower for the procedure, which is connected to the board generating the

electromagnetic field and gets input from the transducer (LG) that is used to navigate to the lesions. ENB can be performed under conscious sedation or general anesthesia. We generally utilize general anaesthesia because of the time it may take to navigate to reach lesions in the lung and sometimes, a brief "breath-hold" may be helpful to accurately sample a lesion moving significantly with breathing.

At the time of the procedure, the patient is laid on a board that creates an electromagnetic field that encompasses the patient's thorax. Sensors similar to EKG leads are placed on the patient's chest and the electromagnetic probe or LG is passed through the working channel of the bronchoscope and is used to synchronize the virtual bronchoscopy with the patient's real-time anatomy. Without accurate synchrony of real-time anatomy and virtual bronchoscopy, navigation is not feasible. The current software automatically does the registration when the LG is advanced in various airways. After synchronization, the LG, which is steerable and sheathed in a catheter, is used to follow the pre-planned endobronchial pathway making required turns as guided by the software or by trial-and-error method to reach the lesion. The position of the catheter tip and its proximity to the lesion are seen on the computer screen in the axial, sagittal, and coronal planes during navigation. After the lesion is reached, the position of the LG and EWC can be checked by fluoroscopy. The LG is then removed from EWC and biopsy tools are then passed down the EWC to sample the desired lesion. The radial UM-EBUS probe can also be passed down the EWC prior to biopsy to confirm the position of lesion.

Thus far, most studies published in the English language are non-randomized studies. The first studies tested the feasibility and accuracy of using the navigation system in humans and had series of approximately 20 patients. After these showed promise, studies with larger series (>20 patients) reported diagnostic yields ranging from 62.5% to 85%.<sup>[51-55]</sup> Two recent studies published in 2012 showed yields > 80%, which may reflect improved operator skills over time and improvement in software and catheter devices,<sup>[53,55]</sup> although selection bias may have played a role. The added time for navigation during bronchoscopy ranges from an additional from 7 min to 70 min.<sup>[51-53,55]</sup> Some studies have suggested increased yield as the lesion size increases, whereas more recent studies have not found this correlation.<sup>[51-53]</sup>

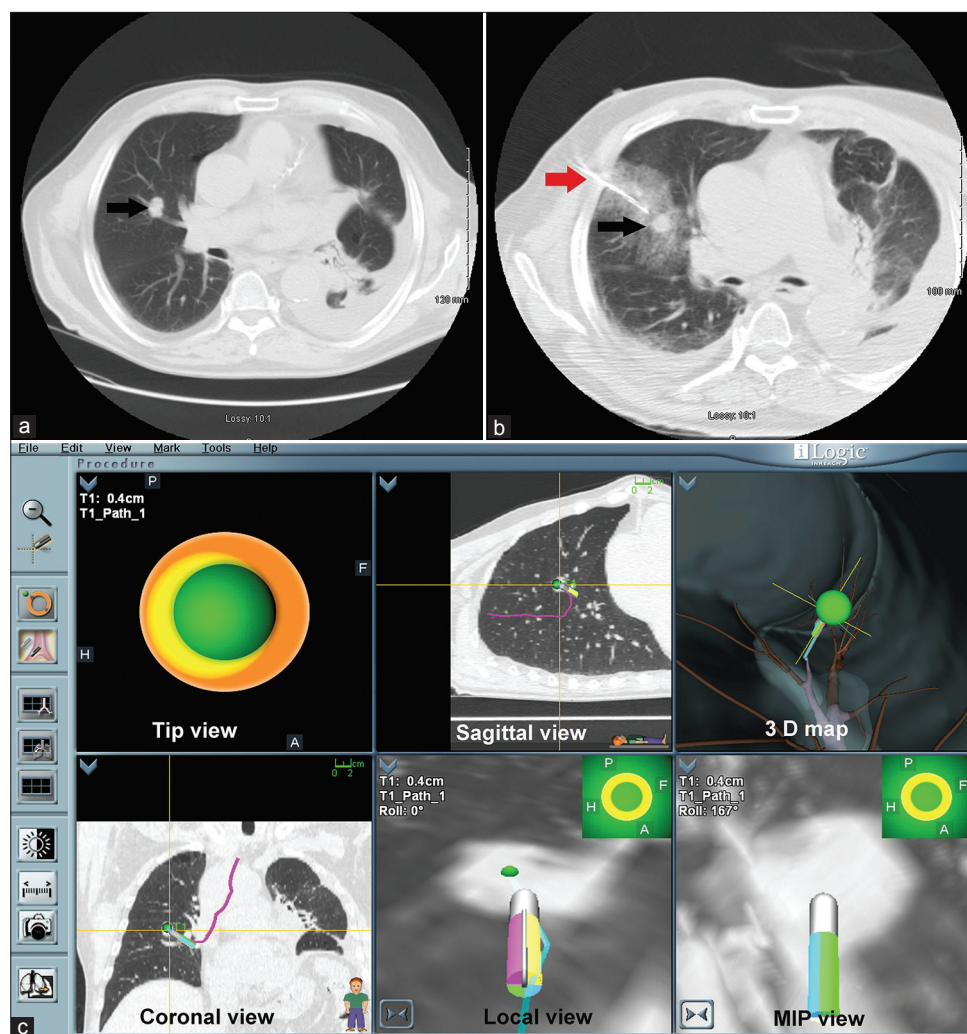
ENB can also be used to sample mediastinal and hilar lymph nodes. The location of transbronchial needle biopsy is mapped prior to the procedure as with lung lesions. Most ENB lymph node sampling does not require planning a route to the lymph node because of the close proximity of the lymph nodes to the airway. The contrast of the virtual

bronchoscopy can be changed to show where the lymph node is on the external wall of the bronchus. The data on this utility of ENB are extremely limited although two studies reported yield between 94% and 100%.<sup>[56,57]</sup> The CP-EBUS has overshadowed ENB in this role but ENB may be beneficial in sampling lymph nodes adjacent to smaller airways, where CP-EBUS cannot reach due to its size or in facilities where CP-EBUS is not available.

Another FDA approved use for ENB is placement of fiducials to help with radiotherapy planning. One study showed that CT-guided fiducial placement resulted in pneumothorax in 8/15 patients. Six of those 8 patients required a chest tube while none of the 8 patients with ENB-guided fiducial placement had pneumothorax.<sup>[58]</sup> Similar fiducial position stability was noted in both groups.<sup>[58]</sup> Another study reported that only 47% of linear fiducials placed by ENB were still in position at the time of radiotherapy planning. Switching

to coiled fiducials achieved a stability rate of 99%.<sup>[59]</sup> ENB has also been anecdotally reported to be helpful for placing markers for localizing lesions during thoracoscopic surgery.

The major drawback of ENB is cost. The equipment and accessories are expensive and an additional chest CT may need to be obtained for planning if the available CT does not meet the software specifics. Some insurance carriers consider it “investigational” and reimbursement can be challenging. The procedures can only be done in rooms and beds that have been evaluated and approved by the company as certain devices may cause magnetic interference. Anatomy synchronization in patients after pneumonectomy can be challenging due to limited reference points to match with virtual bronchoscopy. Similarly, changes during procedure like occurrence of pneumothorax or shifting pleural effusions can displace the target resulting in sampling error<sup>[60]</sup> (as target selection on the virtual CT is not real time). Lesions



**Figure 3:** (a) Computed tomogram (CT) chest showing right lung nodule that was undiagnosed after two CT-guided biopsy attempts. (b) CT biopsy with needle (white arrow) going deep inside lung parenchyma and surrounding hemorrhage. (c) Navigational bronchoscopy screen shot showing successful navigation to the lesion. The diagnosis was adenocarcinoma

that do not have an airway in proximity or leading to them may not be navigable. Due to the presence of the magnetic field, the safety in patients with pacemakers and implantable defibrillators is not clear although limited data suggest that it is safe. The bronchoscope for ENB must have a 2.8 mm working channel and thus it may not be feasible in patients with narrow or stenosed airways and clear visualization of distal smaller airways may not be possible.

Finally, the important question is about when to use ENB. We feel that ENB is a reasonable diagnostic modality in the following situations where clinical suspicion of malignancy is high:

1. When CT-guided biopsy is not feasible like presence of emphysema or location of lesion adjacent to a vessel where bleeding risk is high.
2. When performing bronchoscopy has an additional clinical advantage over TTNA. For example, simultaneous EBUS can help with staging or lavage/cultures may be helpful for work up of concomitant infection or bronchoscopic examination is needed for accurate staging and to determine surgical candidacy.
3. When CT biopsy has previously been non-diagnostic [Figure 3a-c].
4. When the lesion is adjacent to the airway and ENB has very high chance of success. Due to much lower rate of pneumothorax, this may be safer approach for the patient.
5. When multiple lung lesions may need to be biopsied.
6. When additional tissue is needed for subtyping or mutation testing.
7. When placing markers for stereotactic radiation or aiding in lung resection.

## MULTIMODALITY BRONCHOSCOPIC DIAGNOSTIC TECHNIQUES

Recent studies have suggested that using multiple modalities at the time of bronchoscopy can improve the yield significantly and make it comparable to percutaneous CT-guided biopsy and at the same time maintaining the safety profile of bronchoscopy. The combination of virtual bronchoscopy with UM-EBUS with guide sheath and 4.0 mm ultrathin video-bronchoscope for peripheral lesions  $\leq 3$  cm was shown to increase the diagnostic yield of regular bronchoscopy from 67% to 80.4% by the V-NINJA trial group in Japan.<sup>[61]</sup> Another prospective randomized study comparing the combination of UM-EBUS and ENB with each of this modality separately also showed significant increases in yield with combination.<sup>[16]</sup> After ENB was used to navigate to the desired lesion, the radial EBUS was passed down the EWC to confirm location of the lesion and re-navigation was done

if the UM-EBUS did not show that the tip was in lesion. Using the combined modalities increased the diagnostic yield to 88%, whereas individual yields were 69% for UM-EBUS alone and 59% for ENB alone ( $P 0.02$ ). Only transbronchial biopsies were done and fluoroscopy was not used raising the question if the yield could have been even higher.

## CONCLUSION

EBUS has been the best recent technological advance in the field of bronchoscopy and has improved our ability to diagnose, stage, and treat lung cancer. It will soon establish a clear role in the guidelines and algorithms for diagnosis and management of lung cancer. ENB has also enhanced our diagnostic, staging, and treatment abilities. Although better prospective studies are needed, it is clearly very useful in patients who are unable to have surgical resection or CT-guided biopsy and for radiotherapy planning. Combination of virtual bronchoscopy/ENB and UM-EBUS may increase diagnostic yield to a level greater than that found with either modality alone and may be comparable to CT-guided TTNA with significantly lower complication rate as compared to TTNA.

## REFERENCES

1. Travis WD, Rekhtman N. Pathological diagnosis and classification of lung cancer in small biopsies and cytology: Strategic management of tissue for molecular testing. *Semin Respir Crit Care Med* 2011;32:22-31.
2. Dhillon SS, Dhillon JK, Yendamuri S. Mediastinal staging of non-small-cell lung cancer. *Expert Rev Respir Med* 2011;5:835-50.
3. Holty JE, Kushner WG, Gould MK. Accuracy of transbronchial needle aspiration for mediastinal staging of non-small cell lung cancer: A meta-analysis. *Thorax* 2005;60:949-55.
4. Prakash UB, Offord KP, Stubbs SE. Bronchoscopy in North America: The ACCP survey. *Chest* 1991;100:1668-75.
5. Baaklini WA, Reinoso MA, Gorin AB, Sharafkaneh A, Manian P. Diagnostic yield of fiberoptic bronchoscopy in evaluating solitary pulmonary nodules. *Chest* 2000;117:1049-54.
6. Rivera MP, Mehta AC; American College of Chest Physicians. Initial diagnosis of lung cancer: ACCP evidence-based clinical practice guidelines (2<sup>nd</sup> edition). *Chest* 2007;132:131S-148S.
7. Haas AR, Vachani A, Sterman DH. Advances in diagnostic bronchoscopy. *Am J Respir Crit Care Med* 2010;182:589-97.
8. Gomez M, Silvestri GA. Endobronchial ultrasound for the diagnosis and staging of lung cancer. *Proc Am Thorac Soc* 2009;6:180-6.
9. Kurimoto N, Murayama M, Yoshioka S, Nishisaka T, Inai K, Dohi K. Assessment of usefulness of endobronchial ultrasonography in determination of depth of tracheobronchial tumor invasion. *Chest* 1999;115:1500-6.
10. Baba M, Sekine Y, Suzuki M, Yoshida S, Shibuya K, Iizasa T, et al. Correlation between endobronchial ultrasonography (EBUS) images and histologic findings in normal and tumor-invaded bronchial wall. *Lung Cancer* 2002;35:65-71.
11. Miyazu Y, Miyazawa T, Kurimoto N, Iwamoto Y, Kanoh K, Kohno N. Endobronchial ultrasonography in the assessment of centrally located early-stage lung cancer before photodynamic therapy. *Am J Respir Crit Care Med* 2002;165:832-7.
12. Paone G, Nicastri E, Lucantoni G, Dello Iacono R, Battistoni P, D'Angeli AL, et al. Endobronchial ultrasound-driven biopsy in the diagnosis of peripheral lung lesions. *Chest* 2005;128:3551-7.
13. Herth FJ, Eberhardt R, Becker HD, Ernst A. Endobronchial ultrasound-guided



- transbronchial lung biopsy in fluoroscopically invisible solitary pulmonary nodules: A prospective trial. *Chest* 2006;129:147-50.
14. Chao TY, Chien MT, Lie CH, Chung YH, Wang JL, Lin MC. Endobronchial ultrasound-guided transbronchial needle aspiration increases the diagnostic yield of peripheral pulmonary lesions: A randomized trial. *Chest* 2009;136:229-36.
  15. Yamada N, Yamazaki K, Kurimoto N, Asahina H, Kikuchi E, Shinagawa N, et al. Factors related to diagnostic yield of transbronchial biopsy using endobronchial ultrasonography with a guide sheath in small peripheral pulmonary lesions. *Chest* 2007;132:603-8.
  16. Eberhardt R, Anantham D, Ernst A, Feller-Kopman D, Herth F. Multimodality bronchoscopic diagnosis of peripheral lung lesions: A randomized controlled trial. *Am J Respir Crit Care Med* 2007;176:36-41.
  17. Herth FJ, Eberhardt R, Krasnik M, Ernst A. Endobronchial ultrasound-guided transbronchial needle aspiration of lymph nodes in the radiologically and positron emission tomography-normal mediastinum in patients with lung cancer. *Chest* 2008;133:887-91.
  18. Yasufuku K, Pierre A, Darling G, de Perrot M, Waddell T, Johnston M, et al. A prospective controlled trial of endobronchial ultrasound-guided transbronchial needle aspiration compared with mediastinoscopy for mediastinal lymph node staging of lung cancer. *J Thorac Cardiovasc Surg* 2011;142:1393-1400.
  19. Lee HS, Lee GK, Lee HS, Kim MS, Lee JM, Kim HY, et al. Real-time endobronchial ultrasound-guided transbronchial needle aspiration in mediastinal staging of non-small cell lung cancer: How many aspirations per target lymph node station? *Chest* 2008;134:368-74.
  20. Yasufuku K, Nakajima T, Motoori K, Sekine Y, Shibuya K, Hiroshima K, et al. Comparison of endobronchial ultrasound, positron emission tomography, and CT for lymph node staging of lung cancer. *Chest* 2006;130:710-8.
  21. Detterbeck FC, Jantz MA, Wallace M, Vansteenkiste J, Silvestri GA, American College of Chest Physicians. Invasive mediastinal staging of lung cancer: ACCP evidence-based clinical practice guidelines (2<sup>nd</sup> edition). *Chest* 2007;132:202-220S.
  22. Shrager JB. Mediastinoscopy: Still the gold standard. *Ann Thorac Surg* 2010;89:S2084-9.
  23. Park BJ, Flores R, Downey RJ, Bains MS, Rusch VW. Management of major hemorrhage during mediastinoscopy. *J Thorac Cardiovasc Surg* 2003;126:726-31.
  24. Little AG, Rusch VW, Bonner JA, Gaspar LE, Green MR, Webb WR, et al. Patterns of surgical care of lung cancer patients. *Ann Thorac Surg* 2005;80:2051-6.
  25. Steinfurt DP, Liew D, Conron M, Hutchinson AF, Irving LB. Cost-benefit of minimally invasive staging of non-small cell lung cancer: A decision tree sensitivity analysis. *J Thorac Oncol* 2010;5:1564-70.
  26. Ernst A, Anantham D, Eberhardt R, Krasnik M, Herth FJ. Diagnosis of mediastinal adenopathy-real-time endobronchial ultrasound guided needle aspiration versus mediastinoscopy. *J Thorac Oncol* 2008;3:577-82.
  27. Moffatt-Bruce SD, Ross P Jr. Mediastinal abscess after endobronchial ultrasound with transbronchial needle aspiration: A case report. *J Cardiothorac Surg* 2010;5:33.
  28. Huang CT, Chen CY, Ho CC, Yu CJ. A rare constellation of empyema, lung abscess, and mediastinal abscess as a complication of endobronchial ultrasound-guided transbronchial needle aspiration. *Eur J Cardiothorac Surg* 2011;40:264-5.
  29. Botana-Rial M, Núñez-Delgado M, Pallarés-Sanmartín A, Leiro-Fernández V, Represas Represas C, González Silva AI, et al. Intramural hematoma of the pulmonary artery and hemopneumomediastinum after endobronchial ultrasound-guided transbronchial needle aspiration. *Respiration* 2012;83:353-6.
  30. Parker KL, Bizekis CS, Zervos MD. Severe mediastinal infection with abscess formation after endobronchial ultrasound-guided transbronchial needle aspiration. *Ann Thorac Surg* 2010;89:1271-2.
  31. Haas AR. Infectious complications from full extension endobronchial ultrasound transbronchial needle aspiration. *Eur Respir J* 2009;33:935-8.
  32. Navani N, Brown JM, Nankivell M, Woolhouse I, Harrison RN, Jeebun V, et al. Suitability of endobronchial ultrasound-guided transbronchial needle aspiration specimens for subtyping and genotyping of non-small cell lung cancer: A multicenter study of 774 patients. *Am J Respir Crit Care Med* 2012;186:22.
  33. Steinfurt DP, Johnson DF, Irving LB. Incidence of bacteraemia following endobronchial ultrasound-guided transbronchial needle aspiration. *Eur Respir J* 2010;36:28-32.
  34. Dhillon SS, Berim IG. Release of metal particles from needles used for endobronchial ultrasound-guided transbronchial needle aspiration. *Chest* 2012;141:567.
  35. Herth FJ, Annema JT, Eberhardt R, Yasufuku K, Ernst A, Krasnik M, et al. Endobronchial ultrasound with transbronchial needle aspiration for restaging the mediastinum in lung cancer. *J Clin Oncol* 2008;26:3346-50.
  36. Wallace MB, Pascual JM, Raimondo M, Woodward TA, McComb BL, Crook JE, et al. Minimally invasive endoscopic staging of suspected lung cancer. *JAMA* 2008;299:540-6.
  37. Annema JT, van Meerbeeck JP, Rintoul RC, Dooms C, Descheppe E, Dekkers OM, et al. Mediastinoscopy vs endosonography for mediastinal nodal staging of lung cancer: A randomized trial. *JAMA* 2010;304:2245-52.
  38. Hwangbo B, Lee GK, Lee HS, Lim KY, Lee SH, Kim HY, et al. Transbronchial and transesophageal fine-needle aspiration using an ultrasound bronchoscope in mediastinal staging of potentially operable lung cancer. *Chest* 2010;138:795-802.
  39. Nakajima T, Yasufuku K, Suzuki M, Hiroshima K, Kubo R, Mohammed S, et al. Assessment of epidermal growth factor receptor mutation by endobronchial ultrasound-guided transbronchial needle aspiration. *Chest* 2007;132:597-602.
  40. Nakajima T, Yasufuku K. How I do it-optimal methodology for multidirectional analysis of endobronchial ultrasound-guided transbronchial needle aspiration samples. *J Thorac Oncol* 2011;6:203-6.
  41. van Eijk R, Licht J, Schrumpf M, Talebian Yazdi M, Ruano D, Forte GI, et al. Rapid KRAS, EGFR, BRAF and PIK3CA mutation analysis of fine needle aspirates from non-small-cell lung cancer using allele-specific qPCR. *PLoS One* 2011;6:e17791.
  42. Rusch VW, Asamura H, Watanabe H, Giroux DJ, Rami-Porta R, Goldstraw P, et al. The IASLC lung cancer staging project: A proposal for a new international lymph node map in the forthcoming seventh edition of the TNM classification for lung cancer. *J Thorac Oncol* 2009;4:568-77.
  43. Aumiller J, Herth FJ, Krasnik M, Eberhardt R. Endobronchial ultrasound for detecting central pulmonary emboli: A pilot study. *Respiration* 2009;77:298-302.
  44. Dhillon SS, Berim IG, Khushalani N, Gannon J. Detection of a possible case of pulmonary tumour thromboembolism by endobronchial ultrasound. *Monaldi Arc Chest Dis* 2012;77:40-2.
  45. Ohno Y, Hatabu H, Takenaka D, Higashino T, Watanabe H, Ohbayashi C, et al. CT-guided transthoracic needle aspiration biopsy of small ( $\leq 20$  mm) solitary pulmonary nodules. *AJR Am J Roentgenol* 2003;180:1665-9.
  46. Richardson CM, Pointon KS, Manhire AR, Macfarlane JT. Percutaneous lung biopsies: A survey of UK practice based on 5444 biopsies. *Br J Radiol* 2002;75:731-5.
  47. Wiener RS, Schwartz LM, Woloshin S, Welch HG. Population-based risk for complications after transthoracic needle lung biopsy of a pulmonary nodule: An analysis of discharge records. *Ann Intern Med* 2011;155:137-44.
  48. Fish GD, Stanley JH, Miller KS, Schabel SI, Sutherland SE. Postbiopsy pneumothorax: Estimating the risk by chest radiography and pulmonary function tests. *AJR Am J Roentgenol* 1988;150:71-4.
  49. Hiraki T, Mimura H, Gohara H, Shibamoto K, Inoue D, Matsui Y, et al. Incidence of and risk factors for pneumothorax and chest tube placement after CT fluoroscopy-guided percutaneous lung biopsy: Retrospective analysis of the procedures conducted over a 9-year period. *AJR Am J Roentgenol* 2010;194:809-14.
  50. Wang Memoli JS, Nietert PJ, Silvestri GA. Meta-analysis of guided bronchoscopy for the evaluation of the pulmonary nodule. *Chest* 2012;142:385-93.
  51. Bertoletti L, Robert A, Cottier M, Chambonniere ML, Vergnon JM. Accuracy and feasibility of electromagnetic navigated bronchoscopy under nitrous oxide sedation for pulmonary peripheral opacities: An outpatient study. *Respiration* 2009;78:293-300.
  52. Eberhardt R, Anantham D, Herth F, Feller-Kopman D, Ernst A. Electromagnetic navigation diagnostic bronchoscopy in peripheral lung lesions. *Chest* 2007;131:1800-5.
  53. Lamprecht B, Porsch P, Wegleitner B, Strasser G, Kaiser B, Studnicka M. Electromagnetic navigation bronchoscopy (ENB): Increasing diagnostic yield. *Respir Med* 2012;106:710-5.
  54. Makris D, Scherpereel A, Leroy S, Bouchindhomme B, Faviere JB, Remy J, et al.



- Electromagnetic navigation diagnostic bronchoscopy for small peripheral lung lesions. *Eur Respir J* 2007;29:1187-92.
55. Pearlstein DP, Quinn CC, Burtis CC, Ahn KW, Katch AJ. Electromagnetic navigation bronchoscopy performed by thoracic surgeons: One center's early success. *Ann Thorac Surg* 2012;93:944-9.
  56. Gildea TR, Mazzone PJ, Karnak D, Meziane M, Mehta AC. Electromagnetic navigation diagnostic bronchoscopy: A prospective study. *Am J Respir Crit Care Med* 2006;174:982-9.
  57. Wilson DS, Bartlett RJ. Improved diagnostic yield of bronchoscopy in a community practice: Combination of electromagnetic navigation system and rapid on-site evaluation. *J Bronchology Interv Pulmonol* 2007;14:227-32.
  58. Kupelian PA, Forbes A, Willoughby TR, Wallace K, Mañon RR, Meeks SL, et al. Implantation and stability of metallic fiducials within pulmonary lesions. *Int J Radiat Oncol Biol Phys* 2007;69:777-85.
  59. Schroeder C, Hejal R, Linden PA. Coil spring fiducial markers placed safely using navigation bronchoscopy in inoperable patients allows accurate delivery of CyberKnife stereotactic radiosurgery. *J Thorac Cardiovasc Surg* 2010;140:1137-42.
  60. Seijo LM. Electromagnetic Navigation Bronchoscopy. *Pakistan J Chest Med* 2012;18:8-12.
  61. Ishida T, Asano F, Yamazaki K, Shinagawa N, Oizumi S, Moriya H, et al. Virtual bronchoscopic navigation combined with endobronchial ultrasound to diagnose small peripheral pulmonary lesions: A randomised trial. *Thorax* 2011;66:1072-7.

**How to cite this article:** Dhillon SS, Dexter EU. Advances in bronchoscopy for lung cancer. *J Carcinog* 2012;11:19.

**Source and Support:** None **Conflict of Interest:** None declared.

## AUTHOR'S PROFILE

**Dr. Samjot Singh Dhillon**, Department of Medicine-Pulmonary Medicine and Thoracic Oncology, Roswell Park Cancer Institute, and Department of Medicine, State University of New York at Buffalo, New York, USA.

**Dr. Elisabeth U. Dexter**, Department of Thoracic Surgery, Roswell Park Cancer Institute, and Department of Surgery, State University of New York at Buffalo, New York, USA.



Journal of Carcinogenesis is published for Carcinogenesis Press by Medknow Publications and Media Pvt. Ltd.

Manuscripts submitted to the journal are peer reviewed and published immediately upon acceptance, cited in PubMed and archived on PubMed Central. Your research papers will be available free of charge to the entire biomedical community. Submit your next manuscript to Journal of Carcinogenesis.  
[www.journalonweb.com/jcar/](http://www.journalonweb.com/jcar/)